


A Guide Through the Maze of ECG's



**APAP
Education**

by Steve Evans

Contents

Introduction.....	1
A Guide Through the Maze of ECG's.....	2
Electrical Pathway of the Heart.....	4
About ECG Paper.....	6
Eindhoven's Triangle.....	8
Start of ECG Landmarks.....	9
Some Facts.....	14
11 Point Plan.....	15
11 Point Plan Recap.....	27
ECG Landmarks Recap.....	29
Some More Facts.....	30
Practical Rhythm Recognition.....	32
Rhythm Table.....	54

Introduction

Welcome to "A Guide Through the Maze of ECG's". Its original title was to have been "The Beginners Guide to ECG's" which is what this book tries to be and that is the first book you should read when starting out to read and understand ECG's. It is for medical, nursing and ambulance staff or anybody who needs or wants to understand what they see on their cardiac monitors, which they use in their chosen profession.

When I started to train as an ambulance paramedic, I thought that I would never understand ECG's as all the books seem to use big words and go too deep too soon.

I have written this book as simply as I can using easy to understand words building up to proper names, thereby giving you a greater understanding of ECG's.

May I wish you every success with your quest and hope that this book helps you attain your goal.

Steve Evans

State Registered Paramedic

"A Guide Through the Maze of ECG's"

The importance of ECG recognition is to be able to identify those rhythms that are shockable, those that can go into shockable rhythms and those that do not require treatment.

What follows is not the definitive guide but a start so that you can progress onto the books that go into much more detail.

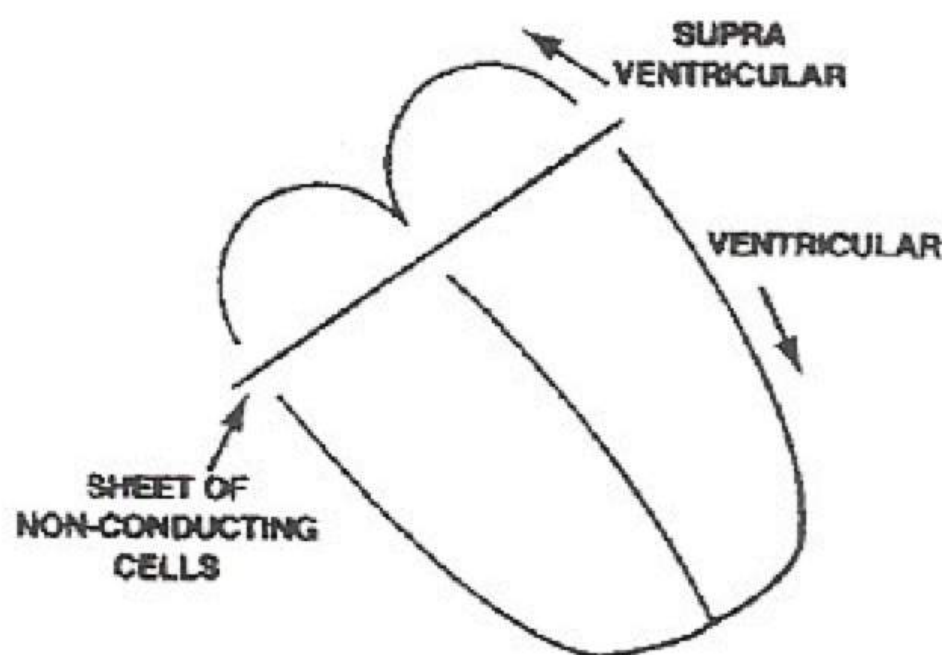
To start with you must think of the heart as divided into two halves, the top half of which is above the ventricles. This is known as SUPRA VENTRICULAR meaning above. These are the ATRIA and as you know, are the receiving chambers of the heart. They have the least amount of muscle mass; both ATRIA contract as one.

The bottom half are the VENTRICLES. When focus of impulse originates it is known as VENTRICULAR. As you know these are the major pumping chambers of the heart and have the greatest amount of muscle mass. Both VENTRICLES contract as one.

It is important to note that the larger the amounts of muscle that is either contracting or relaxing, the larger the movements up or down on the ECG.

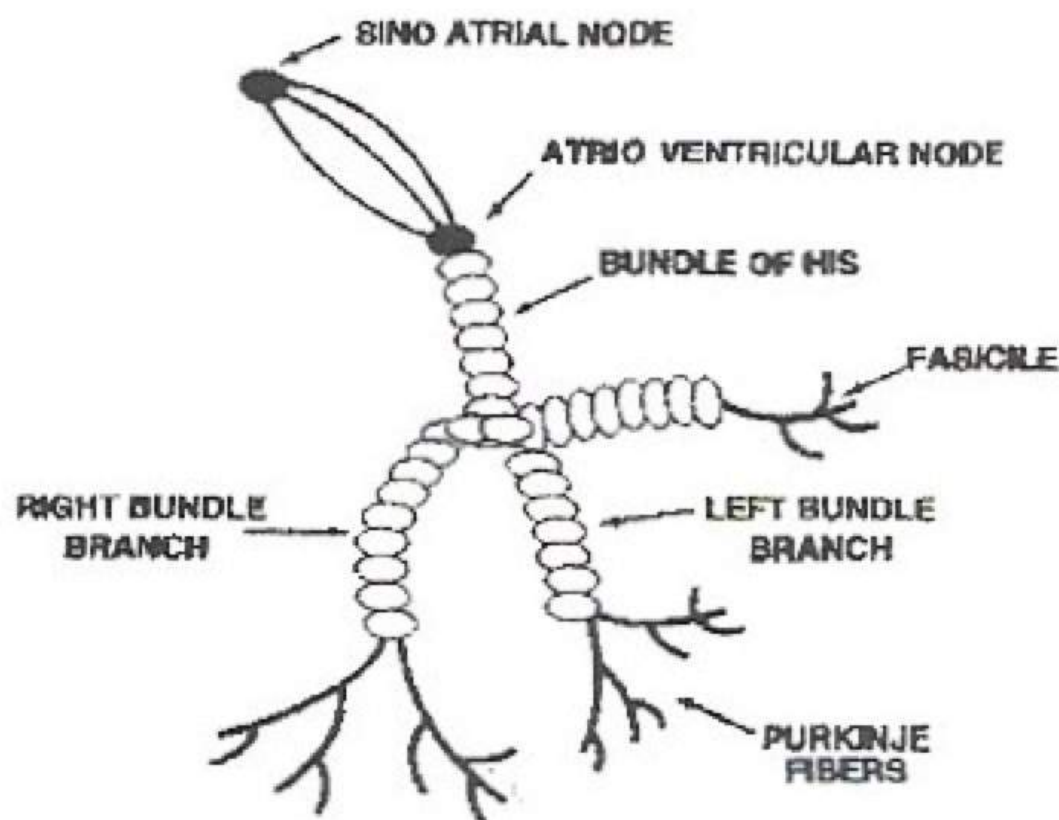
So normally the ATRIA produce a smaller wave than the VENTRICLES whilst either contracting (depolarisation) or relaxing (repolarisation).

A Guide Through the Maze of ECG's



The top and bottom halves are divided by a sheet of NON-CONDUCTING CELLS. Normally the only passageway is through the ATRIO VENTRICULAR NODE, also known as the AV NODE. The job of the AV NODE is to hold onto the impulses from above so that the VENTRICLES have time to fill properly. This is known as the INTER NODAL DELAY.

Electrical Pathway of the Heart



To understand the ELECTRICAL PATHWAY of the heart, try to think of it as a funny shaped fork. The top of the handle is the PACEMAKER of the heart and is known as the SINO ATRIAL NODE, or SA NODE.

The next portion is the postman of the heart and known as the ATRIO VENTRICULAR NODE, also as the AV NODE. This node holds the impulse for 0.1 of the second; this is known as the INTER-NODAL DELAY.

The body of the fork is the BUNDLE OF HIS which carries the impulse onto the RIGHT and LEFT BUNDLE BRANCHES. It is worth pointing out at this stage that as the left ventricle has the most work to do, it is also served with an extra branch known as a FASICLE.

A Guide Through the Maze of ECG's

Finally we end at the prongs. These are the PURKINJE FIBRES, which run throughout the muscle of the heart, the MYOCARDIUM.

Each part of the pathway can initiate an impulse on its own. This is known as the INTRINSIC RATE, but because normally they are getting impulses faster than their own firing rate, they work at that rate.

The SA NODE beats 80 to 60 per minute

The AV NODE beats 60 to 40 per minute

The PURKINJE FIBRES beat 40 to 20 per minute

The SINO ATRIAL NODE (pacemaker) is supplied with two nerves – one to quicken (sympathetic nerve) and one to slow (the vagus or parasympathetic nerve).

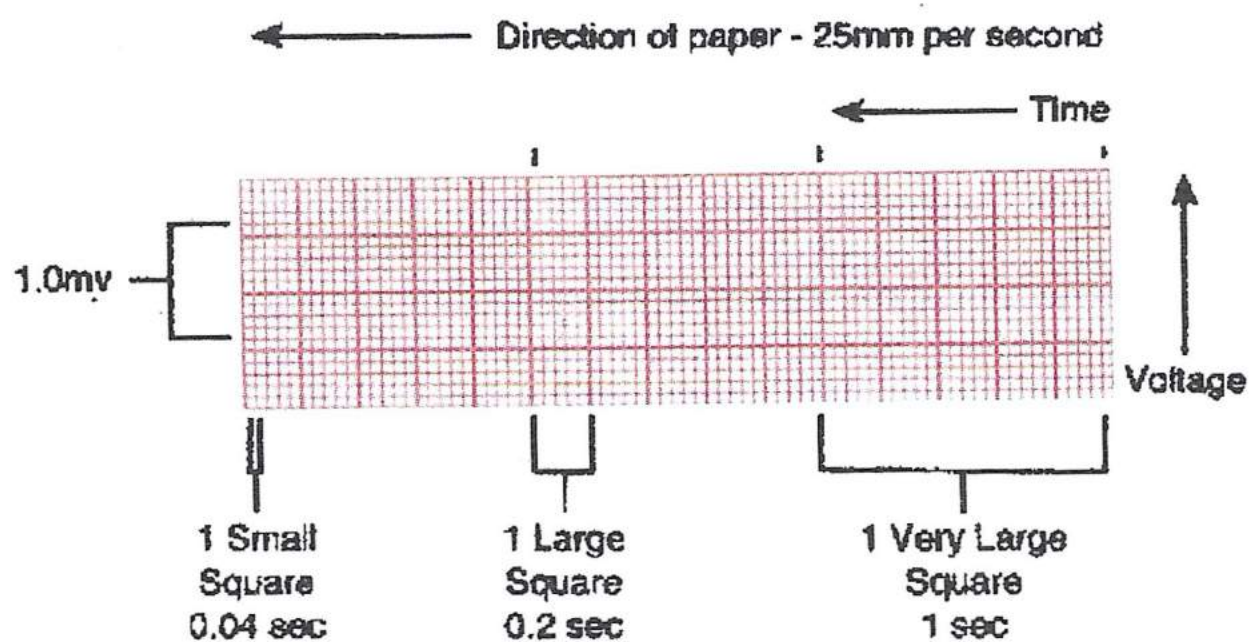
In good health these nerves cancel each other out and so the heart beats at approximately 70 beats per minute.

A Guide Through the Maze of ECG's

About ECG Paper

We now need to understand a few values.

1. ECG paper moves from right to left.
2. ECG paper moves at 25mm per second.
3. Each very large square represents one second of time and is made up of five large squares.
4. Each large square is 0.2 of a second and is made up of five small squares.
5. Each small square is 0.04 of a second.



Horizontal movement is time.

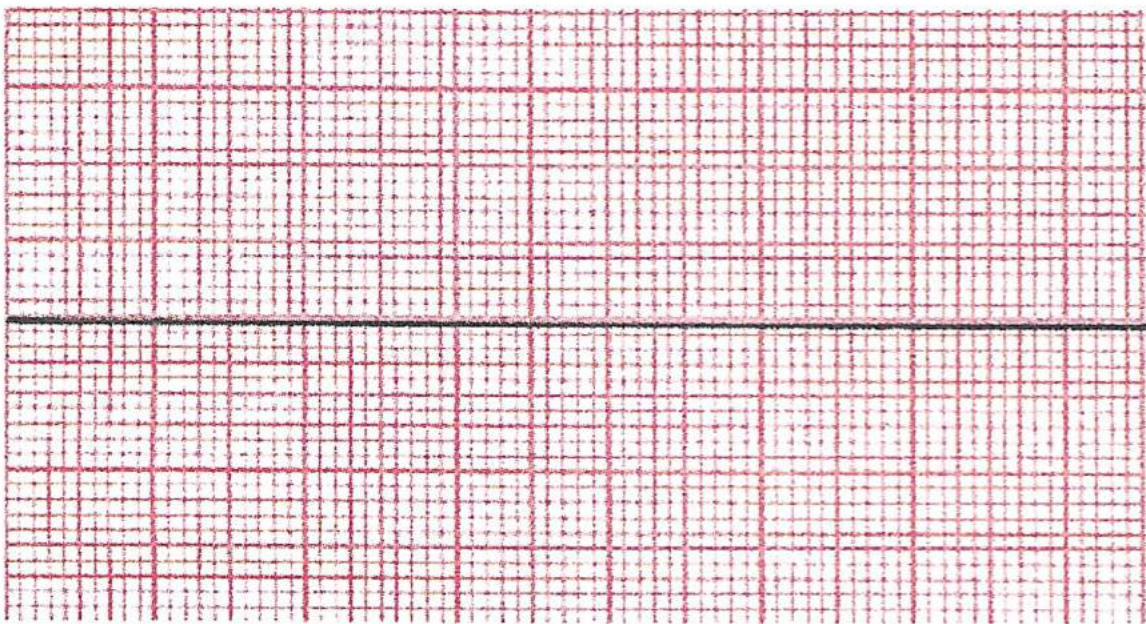
A Guide Through the Maze of ECG's

Vertical movement on ECG paper is an indicator of voltage. This is the impulse given off by any muscle that is contracting (depolarising) or relaxing (repolarising). This is why a patient must be told to relax and not move, as the heart monitor will pick up skeletal muscle movement as well.

The amount of electricity measured is very small and is measured in milli volts (mV).

The values of each large square are 0.5mV, therefore two large squares equal 1.0mV.

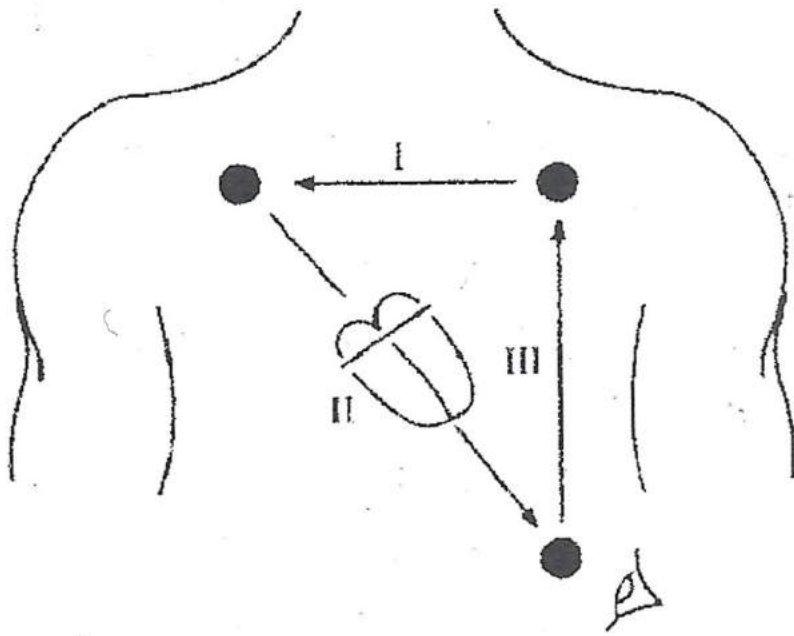
Each ECG monitor is usually calibrated to 1.0mV.



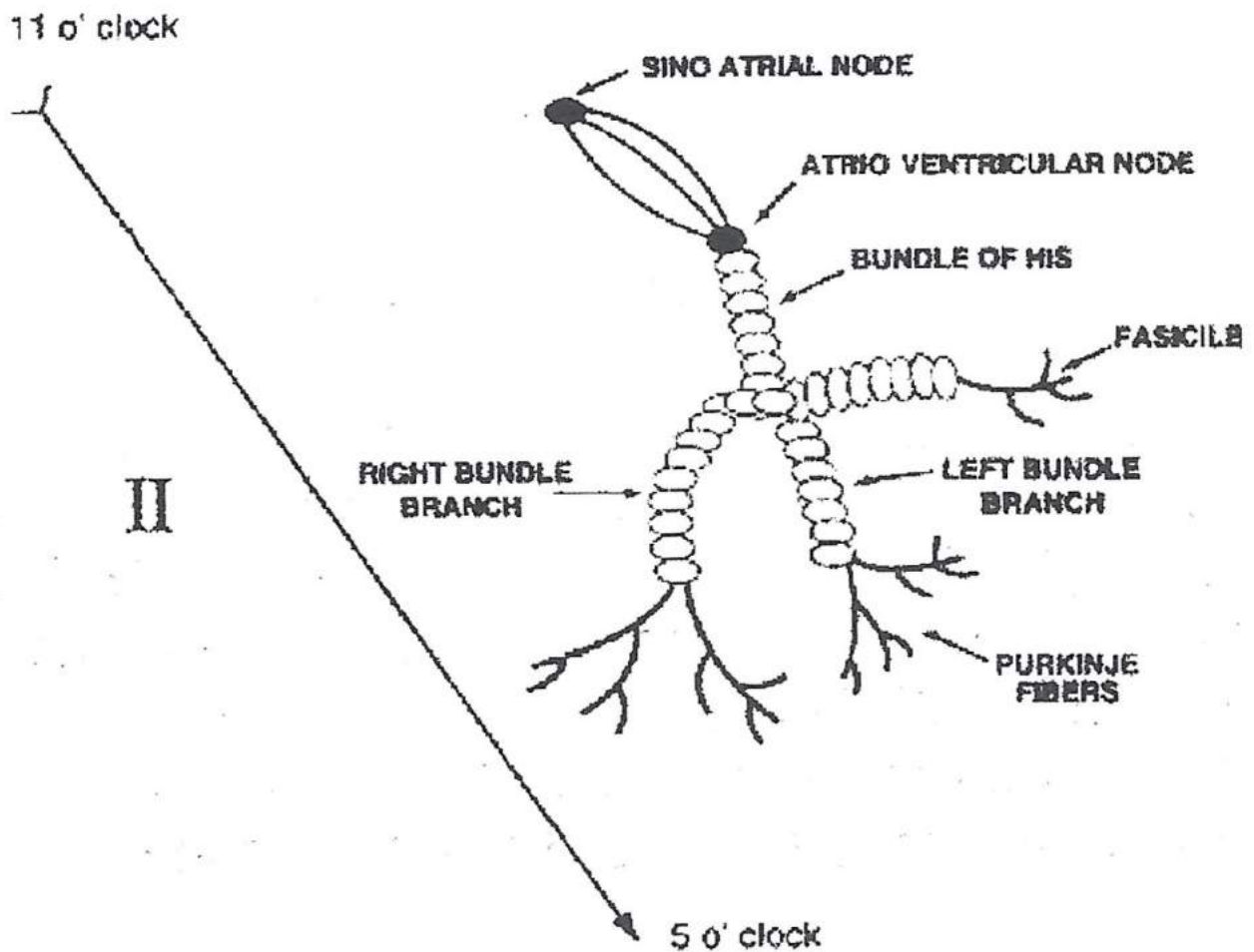
ISO Electric Line (or Baseline)

The central line running through the paper with no movement up or down is known as the ISOELECTRIC LINE (ISO meaning NEUTRAL). Any movement above the line is said to be a POSITIVE DEFLECTION; any movement below the line is said to be a NEGATIVE DEFLECTION. Later we will learn the importance of these movements.

Eindhoven's Triangle



We usually use Eindhoven's Triangle to place our chest electrodes, viewing through Lead 2. This is the most helpful as it looks through the heart from 11 o'clock to 5 o'clock and, as we know, the heart is inclined to the left and so we look down the main electrical pathway.



Start of ECG Landmarks

So if we return to our fork, the impulse is going from the handle to the prongs in a downward flow.

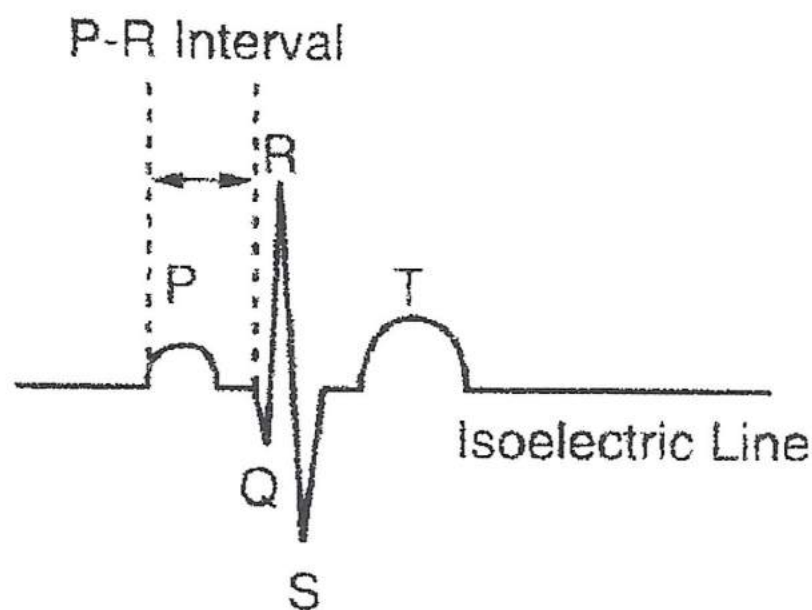
If you require diagnostic ECG's then you must move onto 12 lead ECG's when you fully understand the basics.

In order to keep things simple, I include depolarisation which precedes contraction as one action.

The **FIRST** movement on a normal ECG is the **ATRIA CONTRACTING** (atrial depolarisation). This is known as the **P WAVE**.

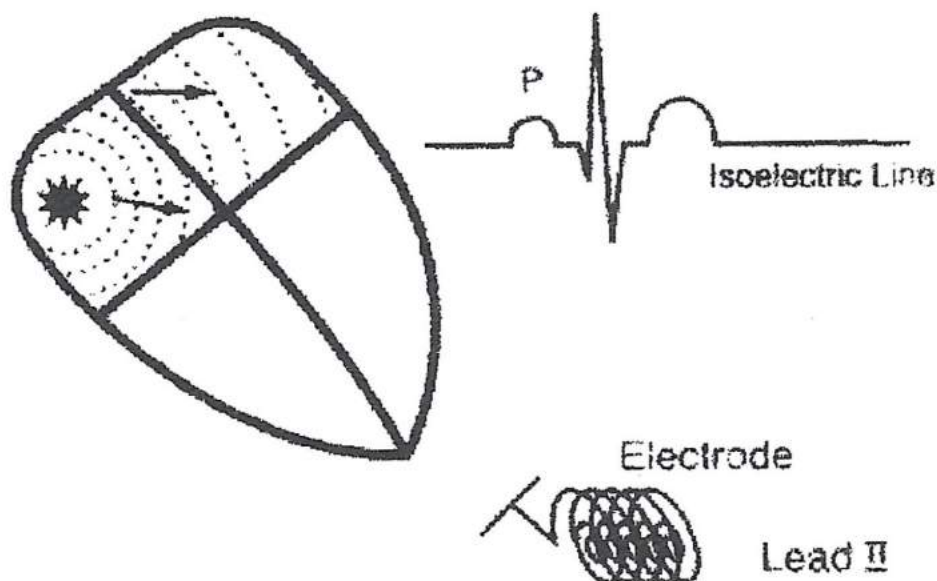
As can be seen below, it is the smallest of the movements. This is due to the smaller amount of muscle in the atria (receiving chambers).

The P-R interval is from the start of atrial contraction to the start of ventricular contraction (ventricular depolarisation) and is normally 0.12 to 0.20 seconds or three to five small squares. This includes the inter nodal delay.

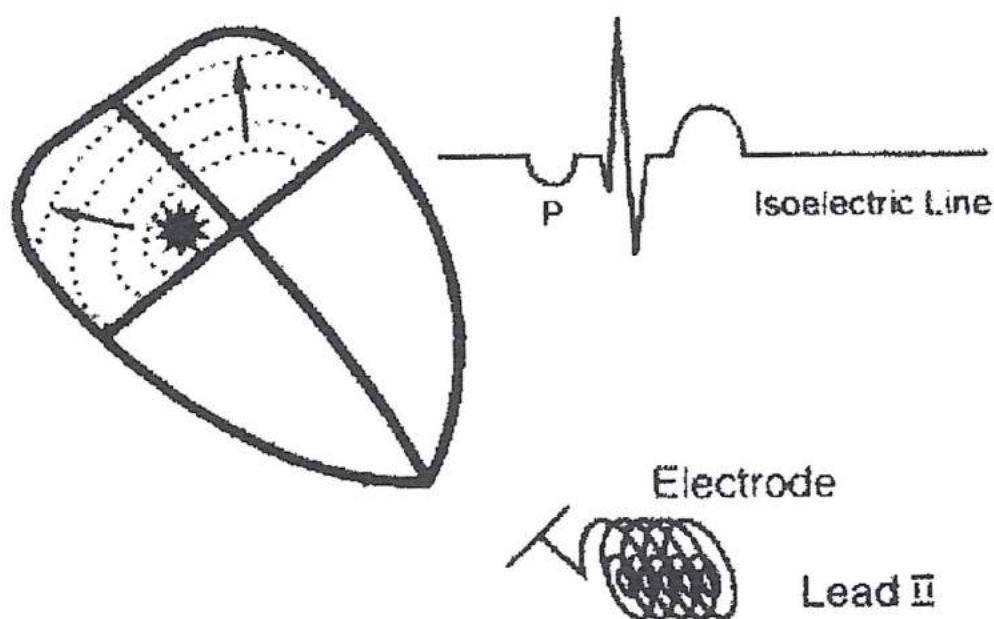


As seen in Lead II

A Guide Through the Maze of ECG's

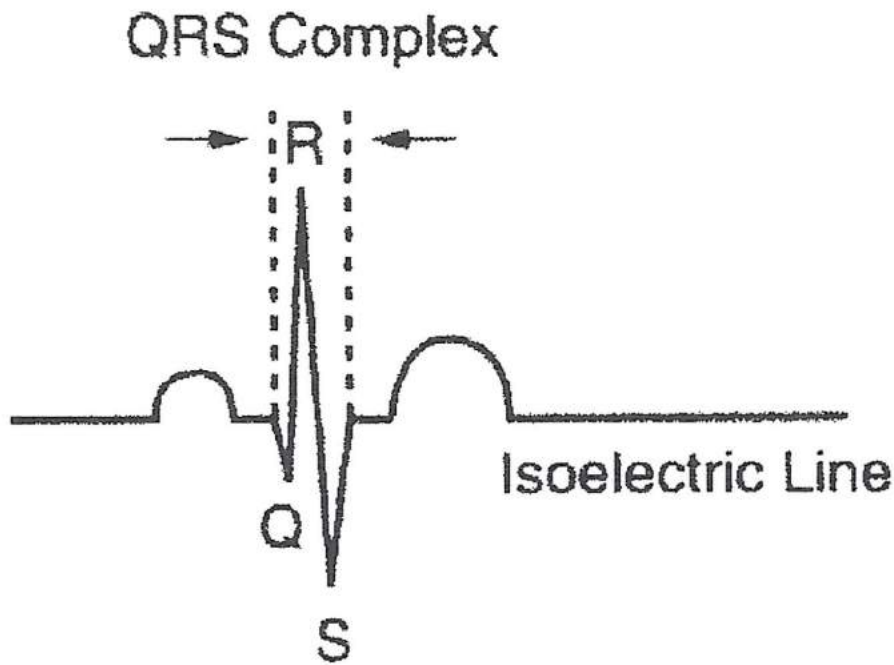


The diagram above shows the impulse originating in the atria. The wave of contraction (excitation) is heading towards the electrode Lead II and so shows as a positive deflection as a normal P Wave.



If the P Wave is upside down it is said to be a negative deflection. Thus the wave of contraction (excitation) is moving away from the electrode Lead II. This tells us that the impulse originated from somewhere different to the normal pacemaker site (the SA node) and could be the AV node, but more on this subject later.

A Guide Through the Maze of ECG's



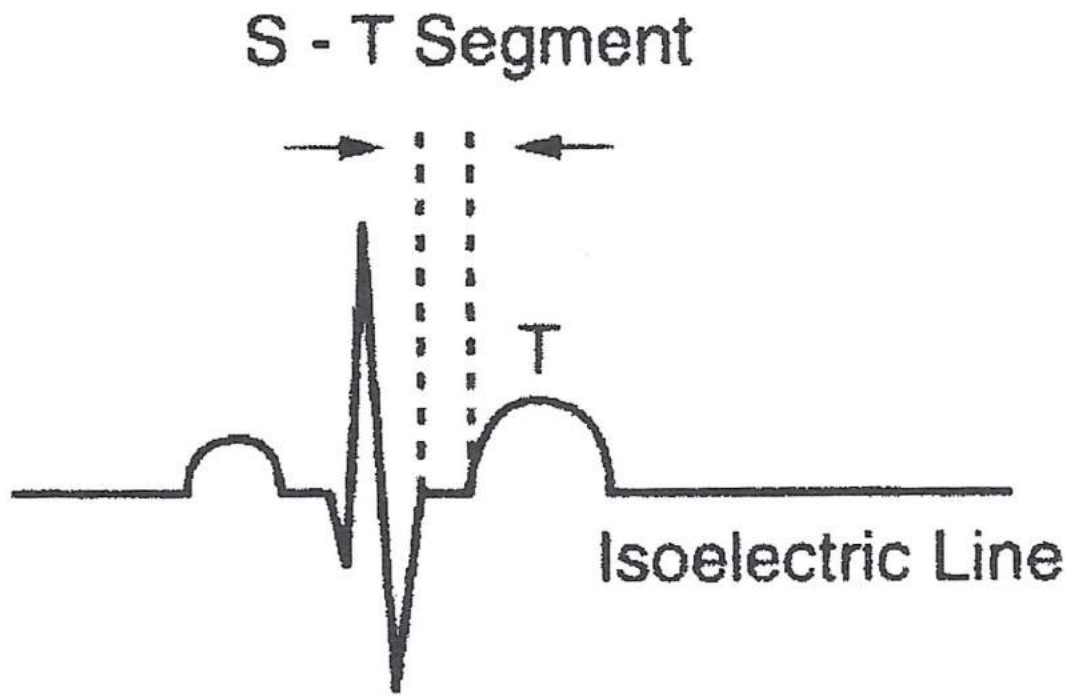
The next part of a normal ECG is the ventricles contracting (ventricular depolarisation) and is known as the QRS complex.

As can be seen, it is much larger in height than the previous P Wave. This is because the ventricles have a much larger mass as they are the major pumping chambers of the heart.

The QRS complex is normally 0.04 to 0.12 seconds, or one to three small squares.

Buried behind the QRS complex are the atria relaxing but due to their size they cannot be seen.

A Guide Through the Maze of ECG's



The S-T segment is from the ventricles contracting to the time the ventricles start to repolarise.

It is normally isoelectric running through the centre of the ECG in a neutral position.

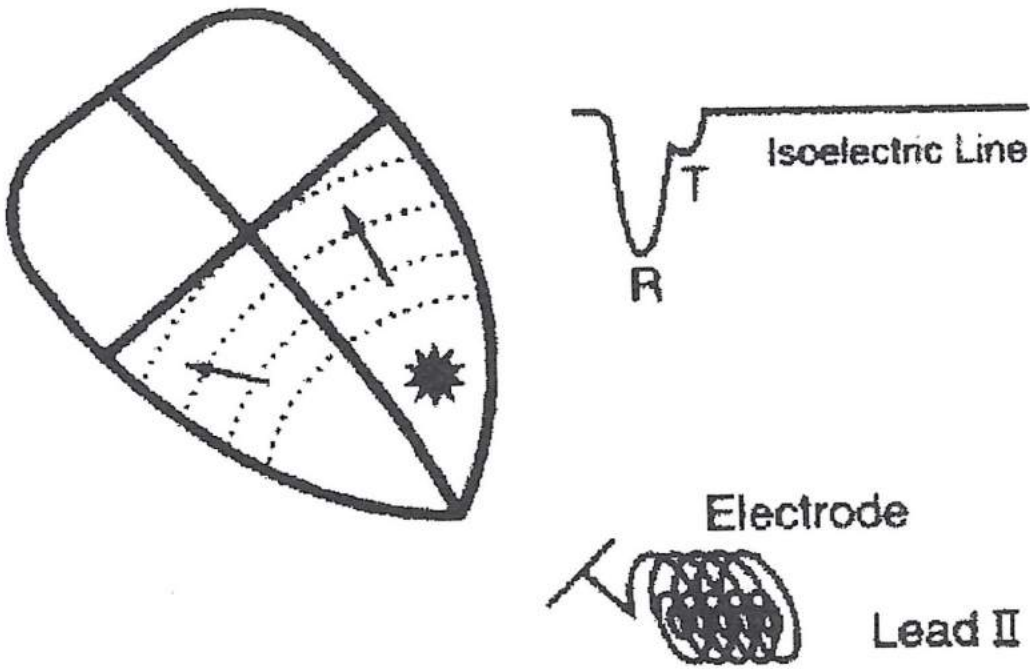
If it is below (depressed) the isoelectric line, it could be a sign of ischaemia or angina. If it is above (elevated) the isoelectric line, it could be a sign of acute myocardial infarction or pericarditis.

Finally, the next movement normally is the ventricles relaxing (ventricular repolarisation). This is known as the T Wave.

It is normally three times the height of the P Wave and is due to the ventricular muscle mass being so much larger.

If the T Wave is inverted (negative deflection) it means the ventricles are relaxing abnormally if seen in Lead II.

A Guide Through the Maze of ECG's



If the impulse originates in the ventricles (purkinje fibres) the wave of contraction (excitation) moves away from the electrode and causes a negative deflection (upside down QRS complex) and since if muscle contracts abnormally, when it relaxes as it is normally followed by an inverted (negative deflection) T Wave.

Some Facts

1. The focus is where the impulse starts and can be anywhere within the heart.
2. There may be more than one focus.
3. If the focus is always in the same position, then it will always appear the same as its neighbour.
4. If the focus is in the atria (supra ventricular) then it will appear in an upward (positive) deflection P Wave or inverted (negative) deflection P Wave.
5. If the focus is supra ventricular and there is no heart block (i.e. death or damage to the AV node) then the QRS complex will be of normal duration unless there is a bundle branch block (i.e. death or damage to either the left or right bundle branches).
6. If the focus is ventricular, then the QRS complex will be wide (greater than 0.12 seconds) and bizarre (not normal shape).
7. If the ventricles contract abnormally, then they relax abnormally.

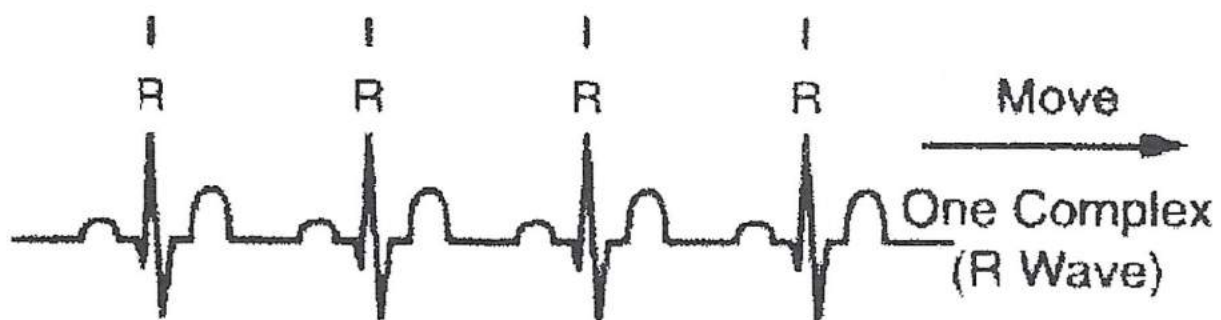
11 Point Plan

1. What is the rhythm?
2. What is the rate?
3. Are there P Waves present?
4. Are all the P Waves the same?
5. Is there a P Wave before each QRS?
6. Is there a QRS after each P Wave?
7. Is the PR interval normal?
8. Is the QRS complex of normal duration?
9. Is the S – T segment isoelectric?
10. Is the T Wave normal?
11. What is the pacemaker site?

A Guide Through the Maze of ECG's

1. What is the rhythm?

It is either regular or irregular. The easiest way to find out is to get a separate piece of paper, pick out all the R Waves and move the separate piece of paper to the right to the next complex (R Wave). If they all line up then it is regular; if they do not line up then it is irregular.



It is important to note the more irregular the rhythm the more life threatening as this affects cardiac output.

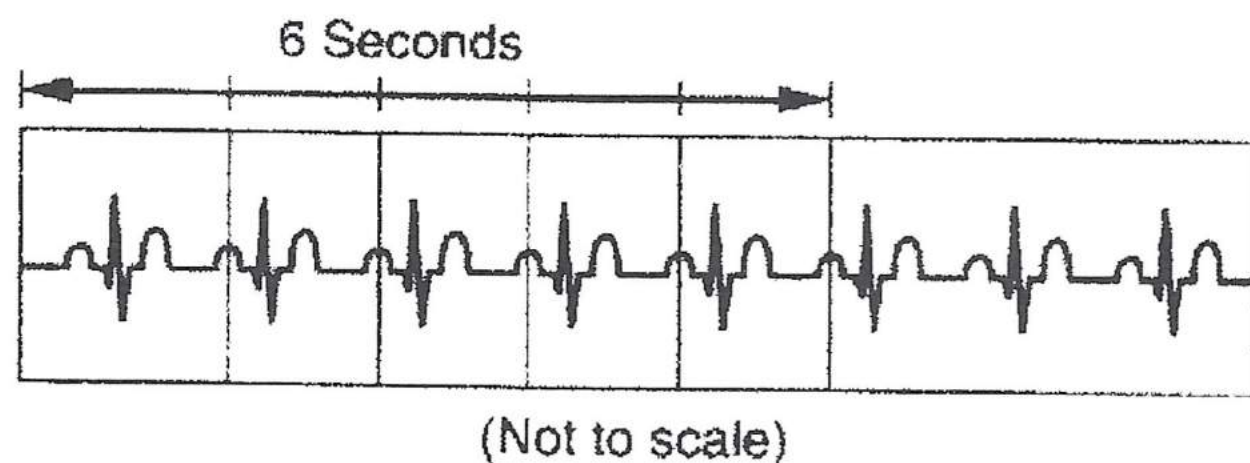
A Guide Through the Maze of ECG's

2. What is the rate?

The rate can be normal (approximately 70 beats per minute); it can be fast (over 100 beats per minute is known as tachycardia) or it can be slow (below 60 beats per minute is known as bradycardia).

This can be calculated in several ways but I prefer the easier which is to pick out six seconds (the marks are normally on the edge of the paper) and count the number of QRS complexes and multiply them by 10.

Six seconds number of QRS's $\times 10$ = heart rate.

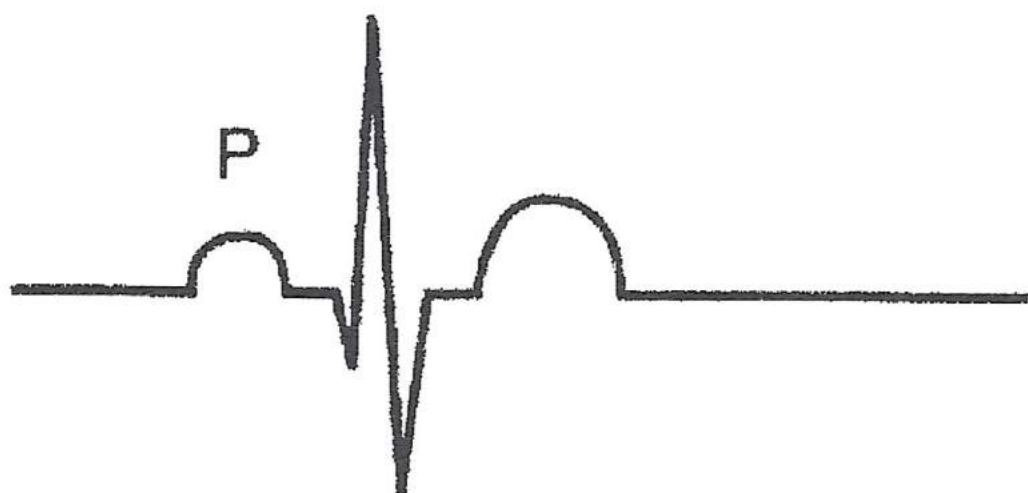

Six QRS in six seconds $\times 10$ = 60 beats per minute, or look at the machine which does the work for you. The alternative is to divide 300 by the number of large squares between complexes.

For example $300/4 = 75$ beats per minute.

A Guide Through the Maze of ECG's

3. Are there P Waves present?

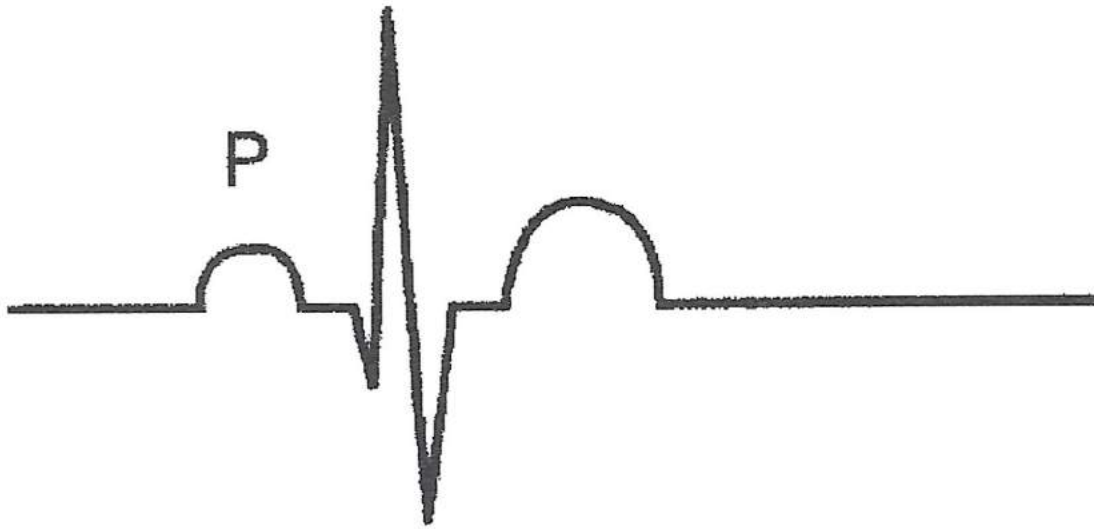


As we know P Waves are normally the first deflection in a normal ECG. If they are present then the focus is in the atria. If they are present they may be inverted (upside down).



This means the impulse is moving away from the electrode Lead II and indicates the foci is junctional or nodal (this is the same thing) and is from the AV node (atria ventricular node). If there are no P Waves then the rhythm will either be junctional or ventricular in origin.

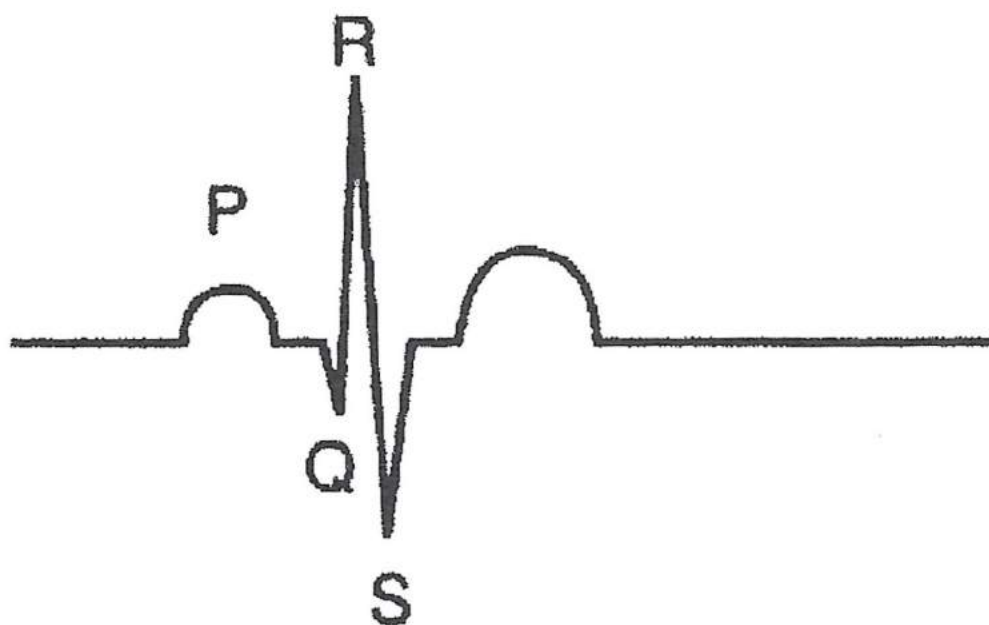
4. Are all the P Waves the same?



If the P Waves all look like their neighbours, then the focus will be in the same place. If the P Waves are different from their neighbours then the focus is in a different place.

A Guide Through the Maze of ECG's

5. Is there a P Wave before each QRS complex?



If yes, then the focus is supra ventricular (atrial).

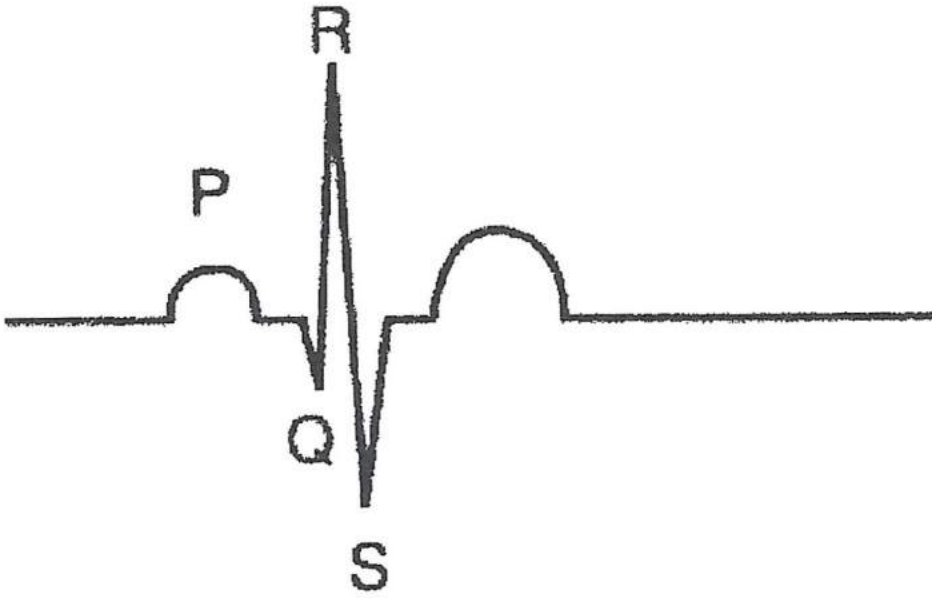
If no, then is there a P Wave before any QRS complexes? If yes, then those with a P Wave are supra ventricular (atrial) and those with no P Wave are either junctional (AV node) or ventricular. In complete heart block (3° Heart block) then there is a complete disassociation between the P Waves and the QRS's.

If no, then focus is either junctional or ventricular.

A P Wave is normally a positive deflection that is above the isoelectric line and denotes atrial focus.

If a P Wave is inverted this denotes a junctional focus.

6. Is there a QRS after each P Wave?

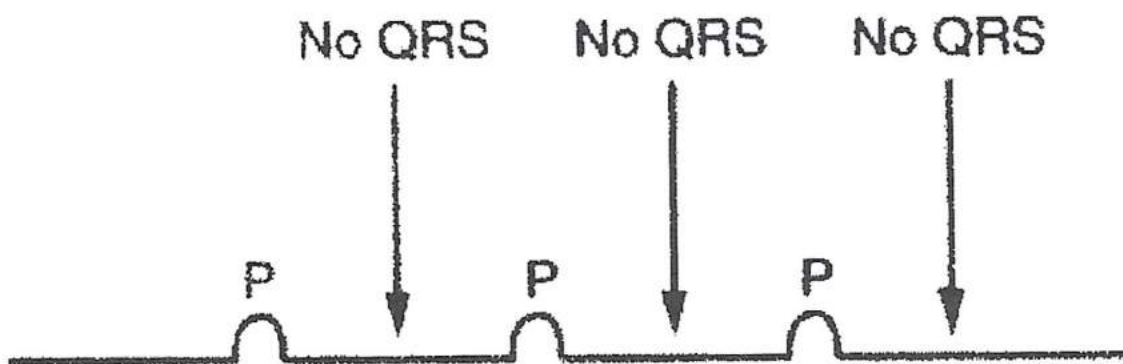


If yes, then normal conductivity is taking place.

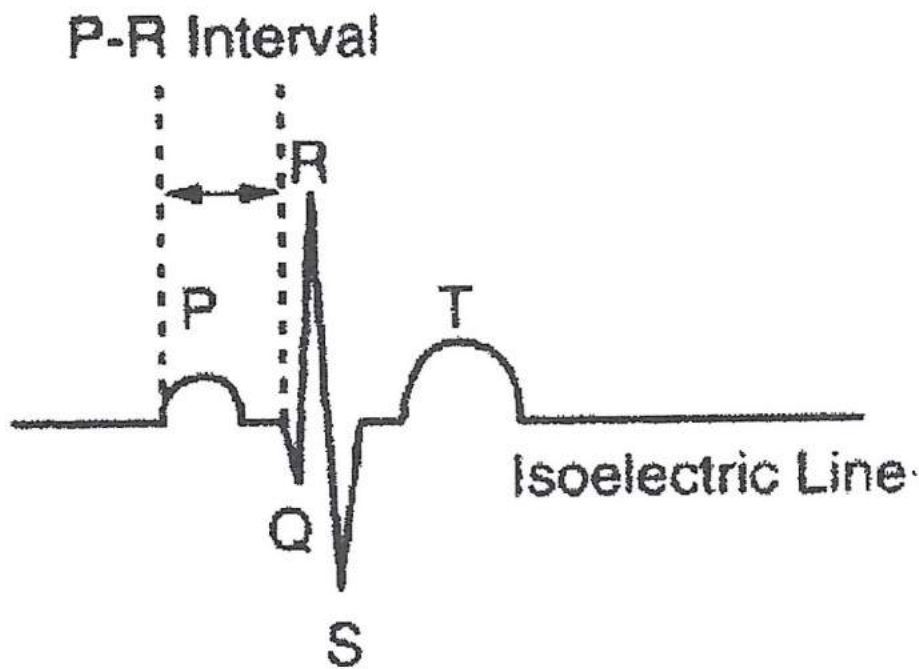
If no, then consider a heart block. That is the AV node is either damaged or dead which can be the result of drugs or disease. Remember the AV node is the only pathway through the sheet of non-conducting cells (normally).

There are four types of heart block (see later).

If no, then it may be ventricular standstill. That is the atria are contracting but the ventricles are not.



7. Is the P-R interval normal?



The P-R interval is from the start of atrial depolarisation to the start of ventricular depolarisation, which includes the internodal delay. It is normally 0.12 to 0.20 seconds or three to five small squares.

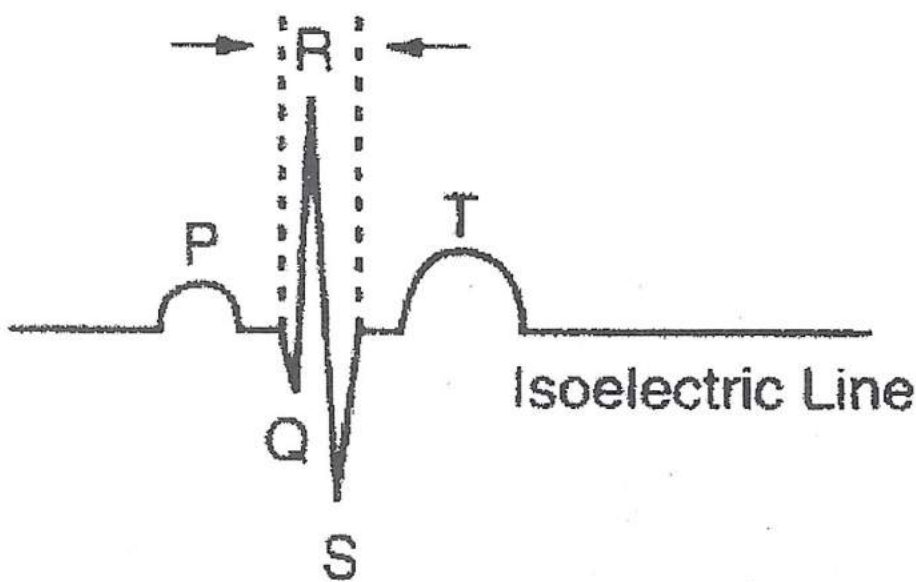
If greater than 0.20 seconds then consider a heart block.

1. If regularly greater than 0.20 seconds, then possibly first degree heart block.
2. If irregularly greater than 0.20 seconds, then possibly second degree Wenckebach or second degree Mobitz type 2 or third degree (complete) heart block.

If there is no QRS complex then there is no P-R interval.

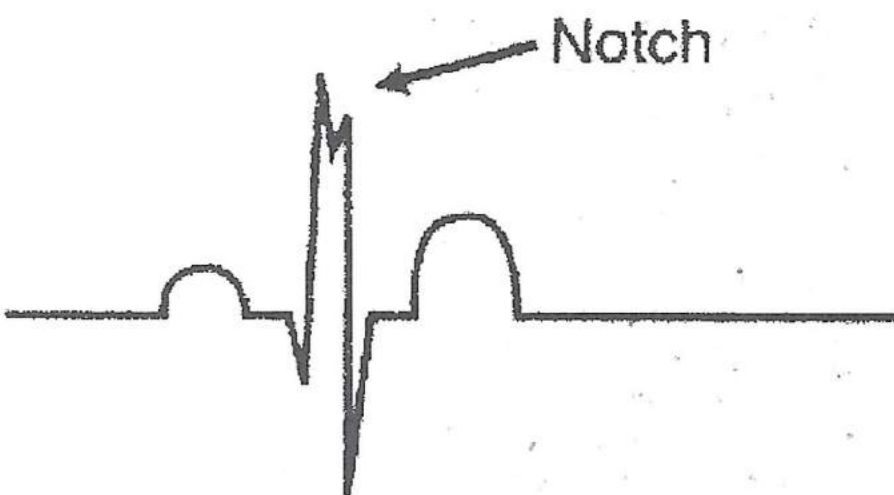
8. Is the QRS complex of normal duration?

QRS Complex

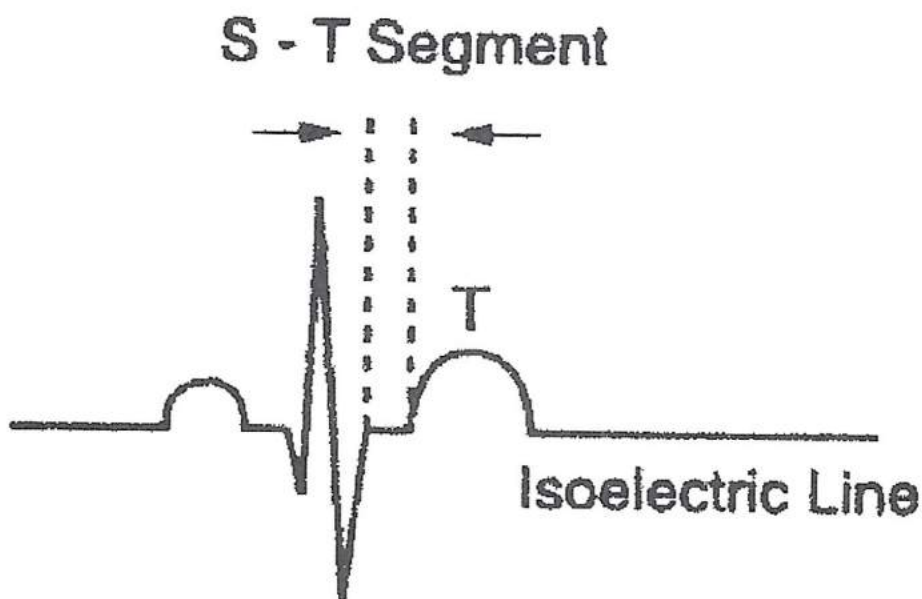


The QRS complex is the time it takes for complete ventricular depolarisation and contraction. The normal QRS complex is 0.04 to 0.12 seconds or one to three small squares.

If QRS is normal then foci is supra ventricular (above the ventricles). If greater than 0.12 seconds then consider a bundle branch block (the time would be slightly greater with a notch in the QRS complex).



9. Is the S-T segment isoelectric?




The S-T segment is when the ventricles pause before relaxing. It is the line that runs through the ECG. Remember ISO means neutral.

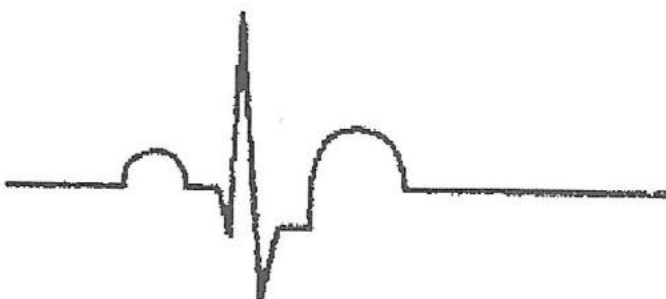If the S-T segment is below the isoelectric line, it is said to be depressed. This can indicate ischaemia or angina, which is a lack of oxygen to the heart muscle.

If the S-T segment is above the isoelectric line, it is said to be elevated. This can indicate death of heart muscle as in acute myocardial infarction.

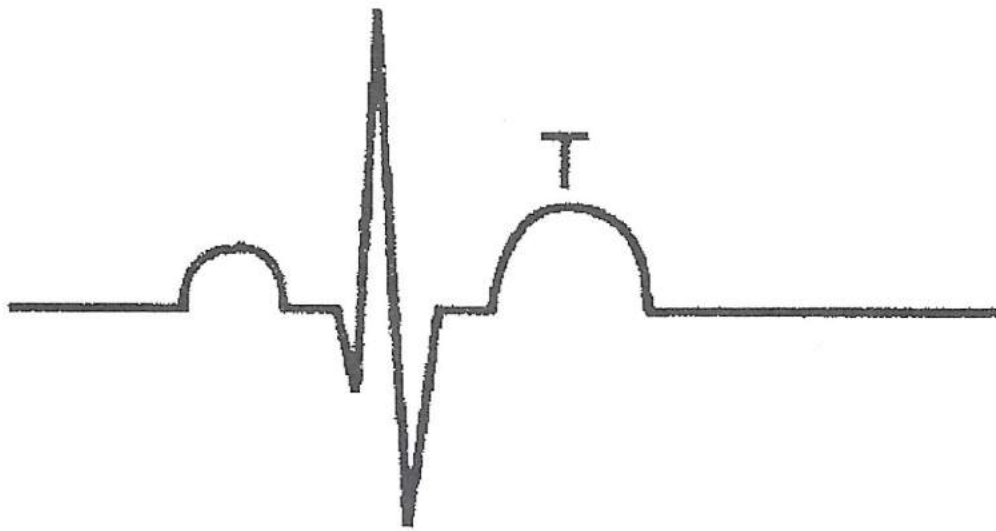
Elevated S - T Segment



Depressed S - T Segment



10. Is the T Wave normal?



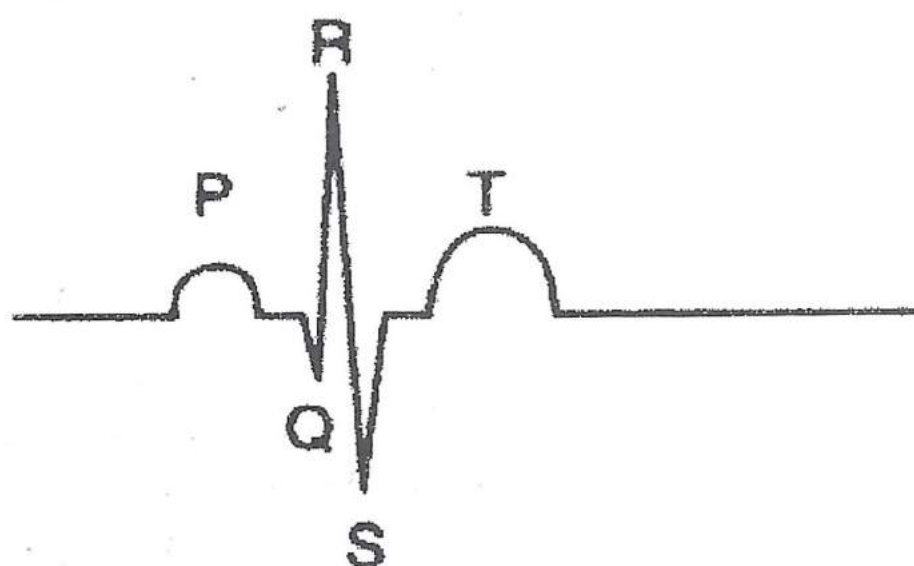
The T Wave represents the ventricles relaxing (repolarisation). The height of the T Wave is normally three times the height of a P Wave as ventricle muscle mass is greater than trial muscle mass.

If the T Wave is positive then that is normal in Lead II.

If the T Wave is inverted (negative) then it means the ventricles are relaxing abnormally which indicates:

1. Ventricular focus. If ventricles contract abnormally they relax abnormally.
2. An old acute myocardial infarction.
3. Myocardial ischaemia.

11. What is the pacemaker site?



If P Waves then atrial foci.

If P Waves inverted then junctional focus. In Lead II.

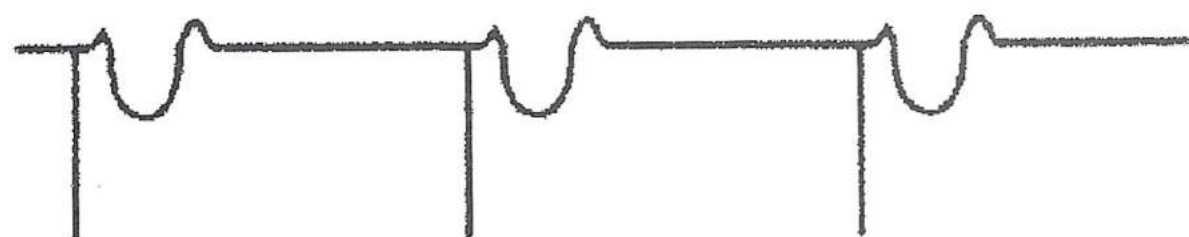
If P Waves after QRS complex, junctional focus.

If QRS complex is normal then supra ventricular focus (atrial or junctional).

If QRS complex wide with P Waves present, then supra ventricular foci.

If QRS complex wide and bizarre without P Waves, then ventricular foci.

If the patient has a pacemaker it will show up as a spike before each beat. Depending on its site, then it may show up as below.



Ventricular Pacemaker

11 Point Plan Recap

1. *What is the rhythm?*

Regular, irregular

2. *What is the rate?*

Fast, normal, slow.

3. *Are there P Waves present?*

If YES, atrial foci.

If NO, junctional or ventricle foci.

4. *Are all the P Waves the same?*

If YES, then same foci.

If NO, then different foci.

5. *Is there a P Wave before each QRS?*

If YES, then atrial foci.

If NO, then junctional or ventricle foci.

6. *Is there a QRS after each P Wave?*

If NO, then ventricular standstill or possible heart block.

7. *Is the P-R interval normal?*

0.12 to 0.20 seconds, 3 - 5 small squares.

If greater than 0.20 seconds, first degree heart block.

8. *Is the QRS normal duration?*

0.04 to 0.12 seconds, 1 - 3 small squares.

If greater than ventricular foci?

Or bundle branch block.

9. *Is the S-T segment isoelectric?*

If elevated, myocardial infarction.

If depressed, ischaemia or angina.

10. *Is the T Wave normal?*

Three time the height of the P Wave.

Or is the T Wave inverted.

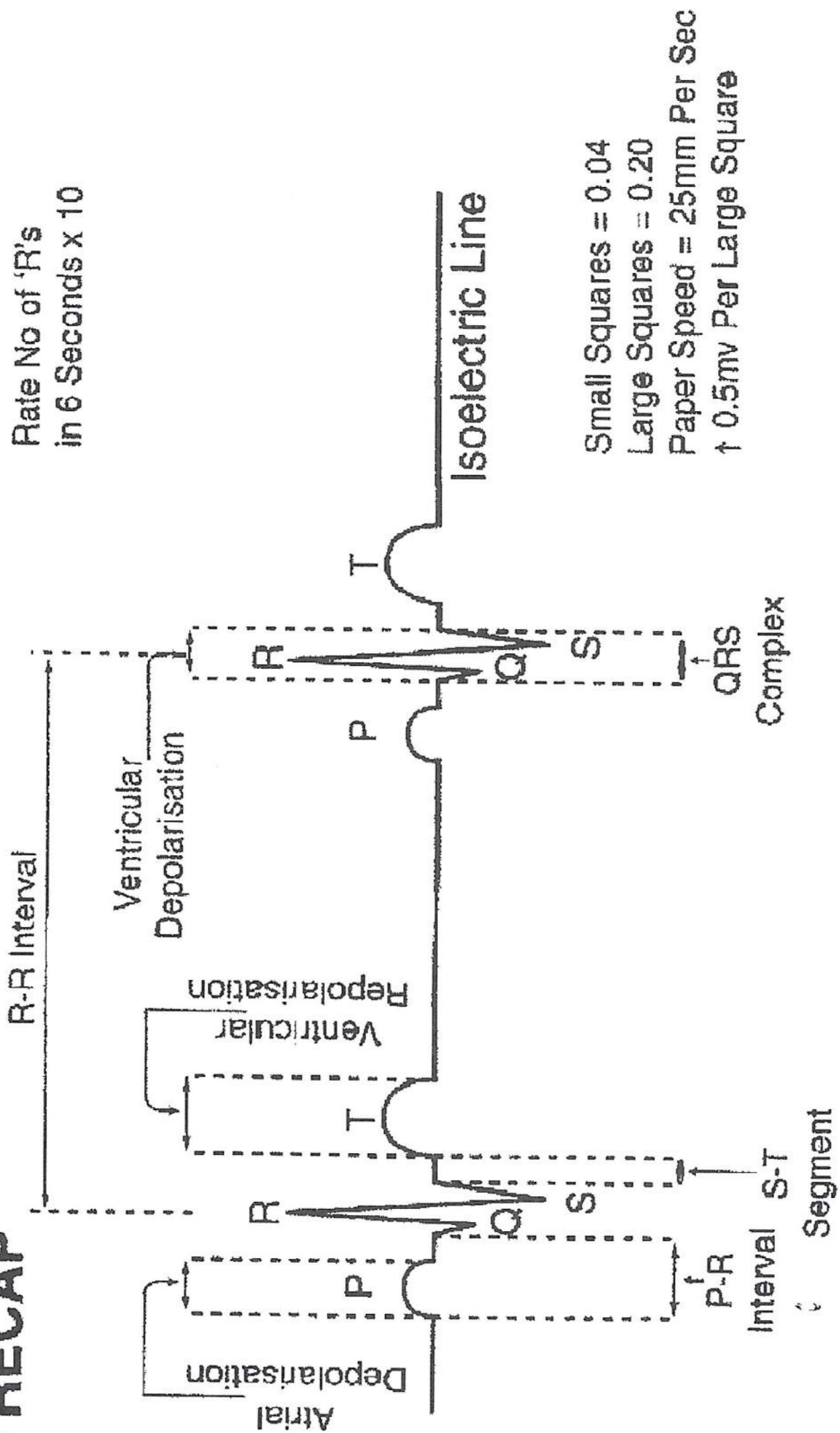
11. *What is the pacemaker site?*

If P Waves, then atrial foci.

If no P Waves, then junctional or ventricular foci.

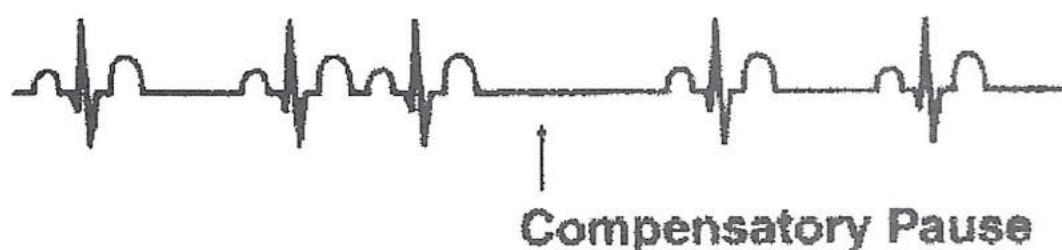
If QRS wide and bizarre, then ventricular foci.

TO RECAP



Some More Facts

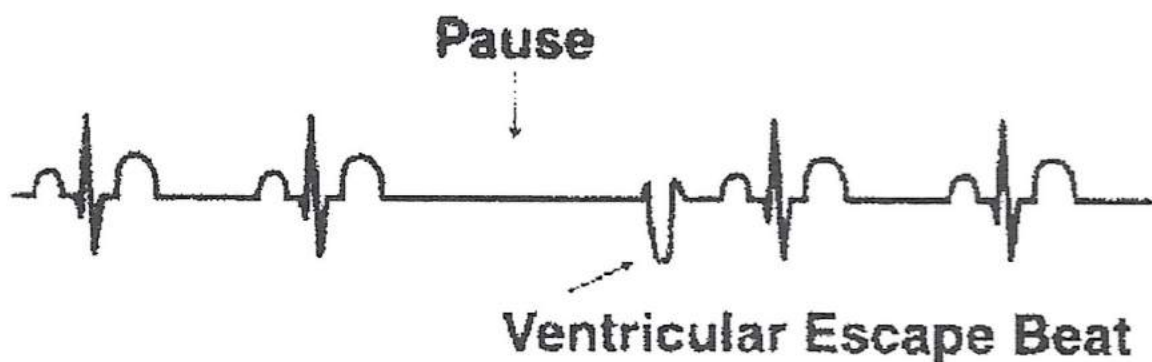
1. All ectopic beats (that is, any premature beat that fires off from an unnatural foci) will have a compensatory pause behind it. It will also appear to have crept up behind its neighbour.



2. Ectopic beats can originate anywhere within the heart; in the atria they are known as Premature Atrial Contractions (PAC's). If from the AV node (atrial ventricular node) they are known as Premature Junctional Contractions (PJC's). If from the Purkinje fibres they are known as Premature Ventricular Contractions (PVC's).
3. Premature ventricular contractions can be unifocal (that is, the same foci [spot] all the time) or multifocal (that is, from a different foci [spot] each time). These are the most life threatening of all the ectopic beats.
4. If every other beat is a PVC it is said to be bigeminy. This can be a normal phenomenon in healthy people so check the patient's condition before you act.
5. If two PVC's are together this is known as a couplet PVC.

A Guide Through the Maze of ECG's

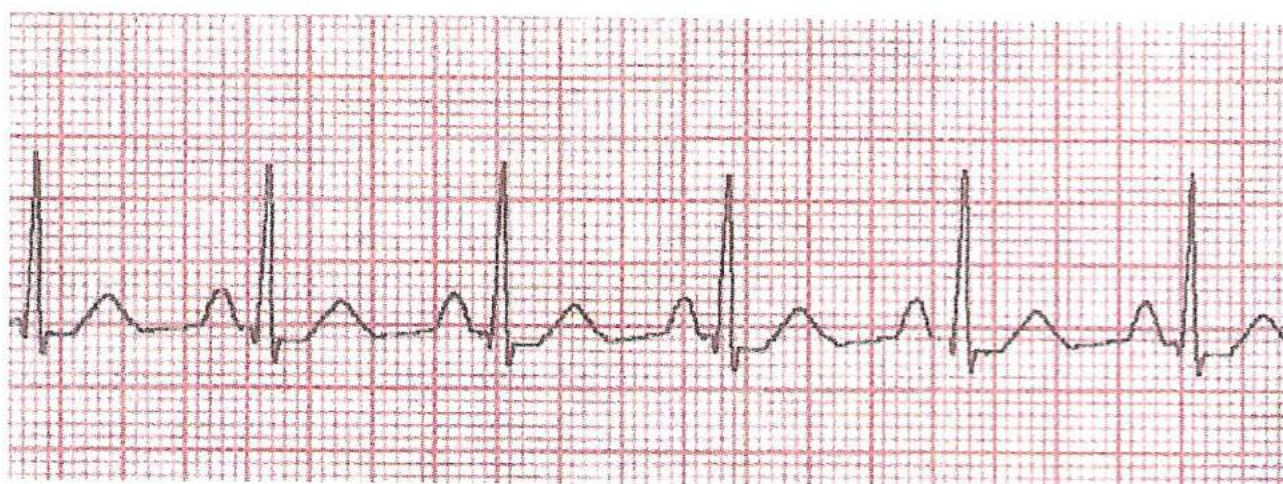6. If more than two PVC's are together then this is known as a run of VT (ventricular tachycardia).
7. Escape beats have a pause before their beat; these are safety beats to protect the body. What happens is that the heart forgets to beat and thanks to the intrinsic factor when one part of the heart does not get an impulse from above, it beats at its own rate.



Practical Rhythm Recognition

We will now go through some of the more common ECG rhythms.

Normal Sinus Rhythm (NSR)



RHYTHM: is regular (remember how to check)

RATE: 70 beats per minute (60 - 100)

P WAVE: Present

P WAVE same: Yes

P WAVE before QRS: Yes

QRS after P WAVE: Yes

P-R INTERVAL: Normal (3 - 5 small squares)

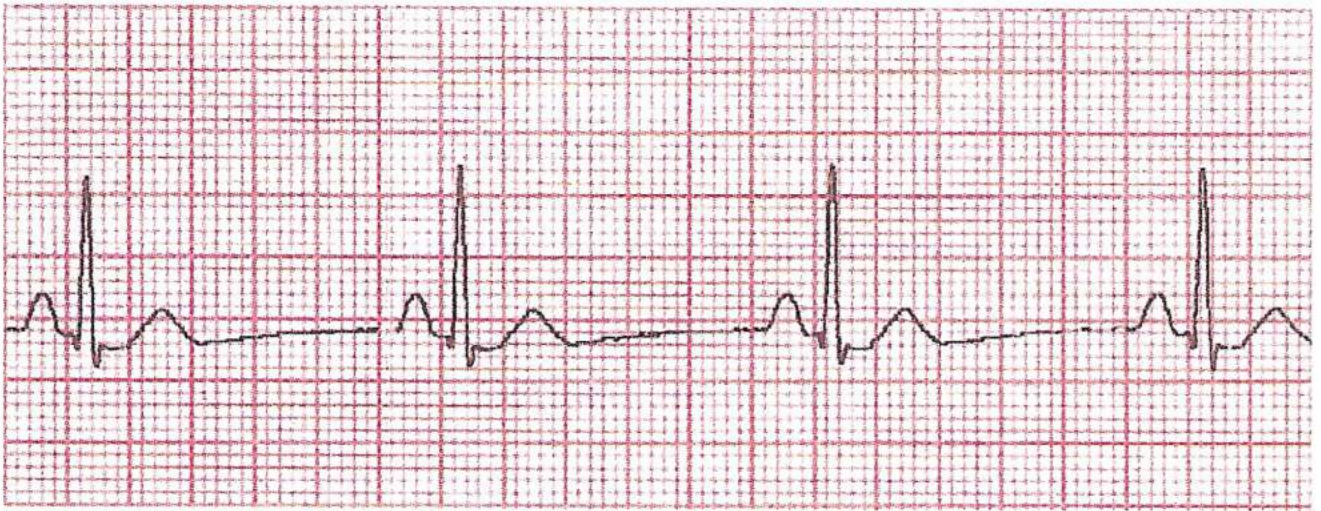QRS COMPLEX: Normal (1 - 3 small squares)

S-T SEGMENT: Isoelectric

T WAVE: Normal (larger than P Wave)

PACEMAKER SITE: Sino atrial node (SA)

Sinus Bradycardia



RHYTHM: Regular

RATE: below 60 beats per minute

P WAVE: Present

P WAVE same: Yes

P WAVE before QRS: Yes

QRS after P WAVE: Yes

P-R INTERVAL: Normal (3 - 5 small squares)

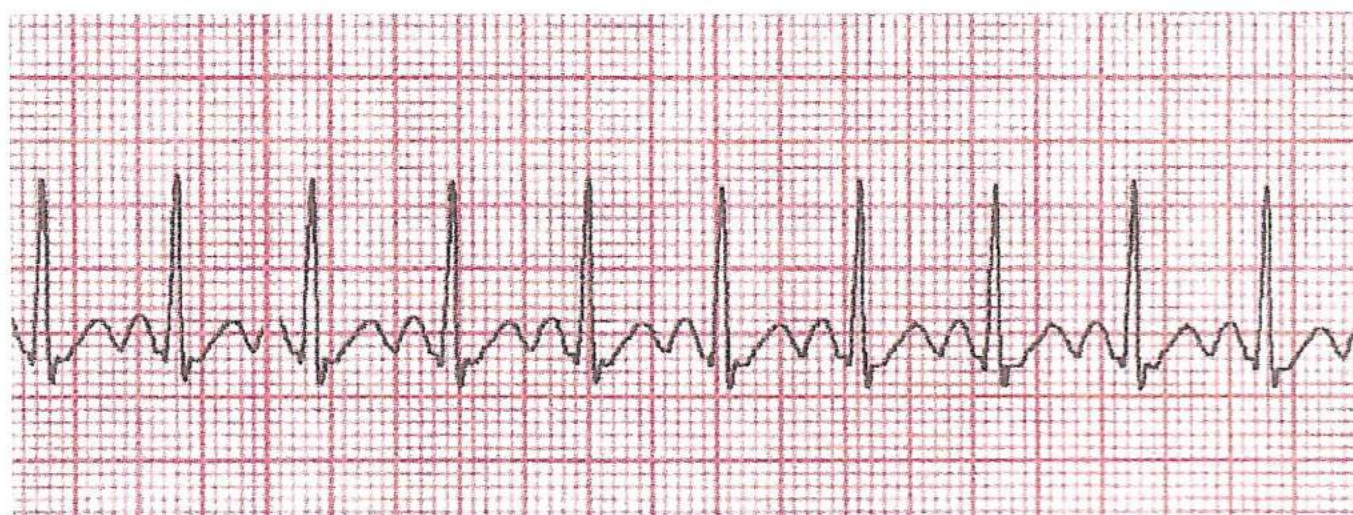
QRS COMPLEX: Normal (1 - 3 small squares)

S-T SEGMENT: Isoelectric

T WAVE: Normal (larger than P Wave)

PACEMAKER SITE: Sino atrial node (SA)

Supra Ventricular Tachycardia



RHYTHM: Regular

RATE: Over 100 beats per minute (160/240)

P WAVE: Not present, buried in previous QRS

P WAVE same: Not present

P WAVE before QRS: Not present

QRS after P WAVE: Unable to see

P-R INTERVAL: Not measurable

QRS COMPLEX: Normal (1 - 3 small squares)

S-T SEGMENT: Isoelectric (see below)

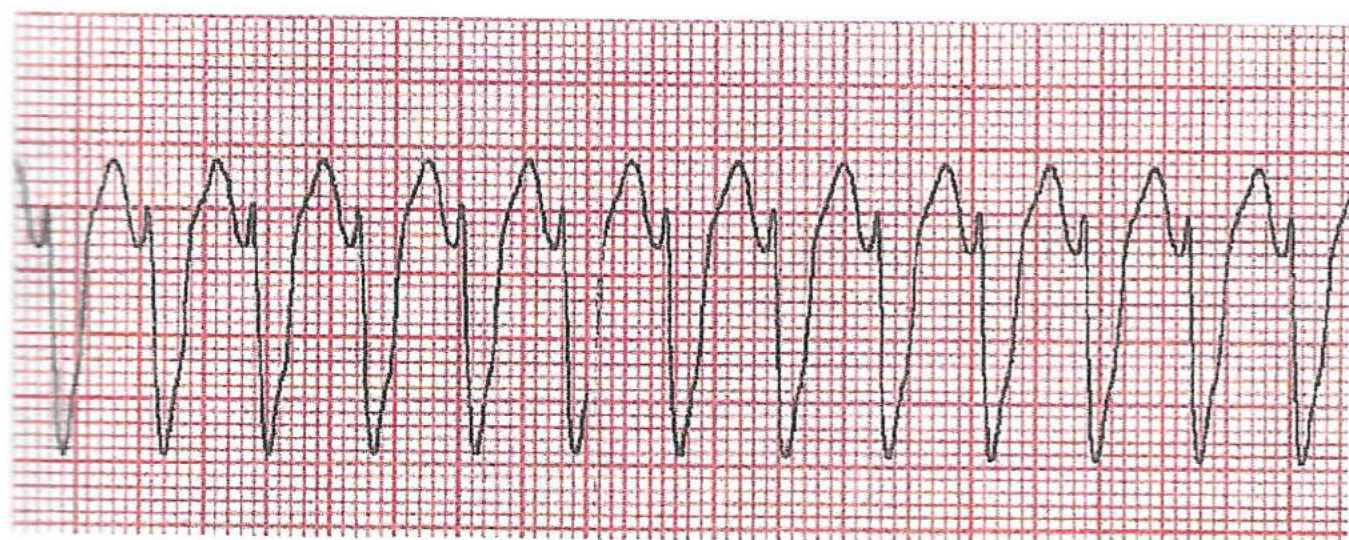
T WAVE: Normal (larger than P Wave)

PACEMAKER SITE: Somewhere in the atria
(above the ventricles [supra])

S-T segment may be depressed due to ischaemia (angina) occurring due to high heart rate.

The rhythm is also known as Narrow Complex Tachycardia.

Ventricular Tachycardia (VT)



RHYTHM: Slightly irregular

RATE: Above 100 beats per minute (100/250)

P WAVE: Absent

P WAVE same: Absent

P WAVE before QRS: Absent

QRS after P WAVE: Absent

P-R INTERVAL: Absent

QRS COMPLEX: Wide and bizarre (< 3 small squares)

S-T SEGMENT: Can be depressed

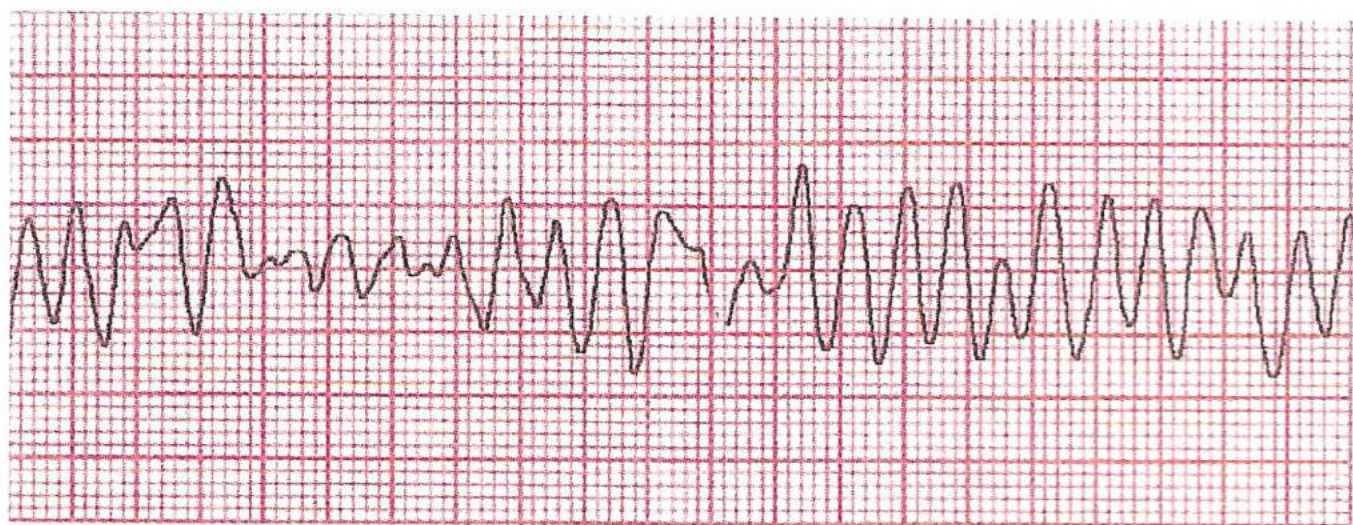
T WAVE: Maybe inverted

PACEMAKER SITE: Ventricular

This rhythm is also known as Wide Complex Tachycardia.

Without a pulse this rhythm is to be treated as a cardiac arrest.

Ventricular Fibrillation (VF)



RHYTHM: Irregular, chaotic

RATE: Not measurable

P WAVE: Absent

P WAVE same: Absent

P WAVE before QRS: Absent

QRS after P WAVE: Absent

P-R INTERVAL: Absent

QRS COMPLEX: Absent

S-T SEGMENT: Absent

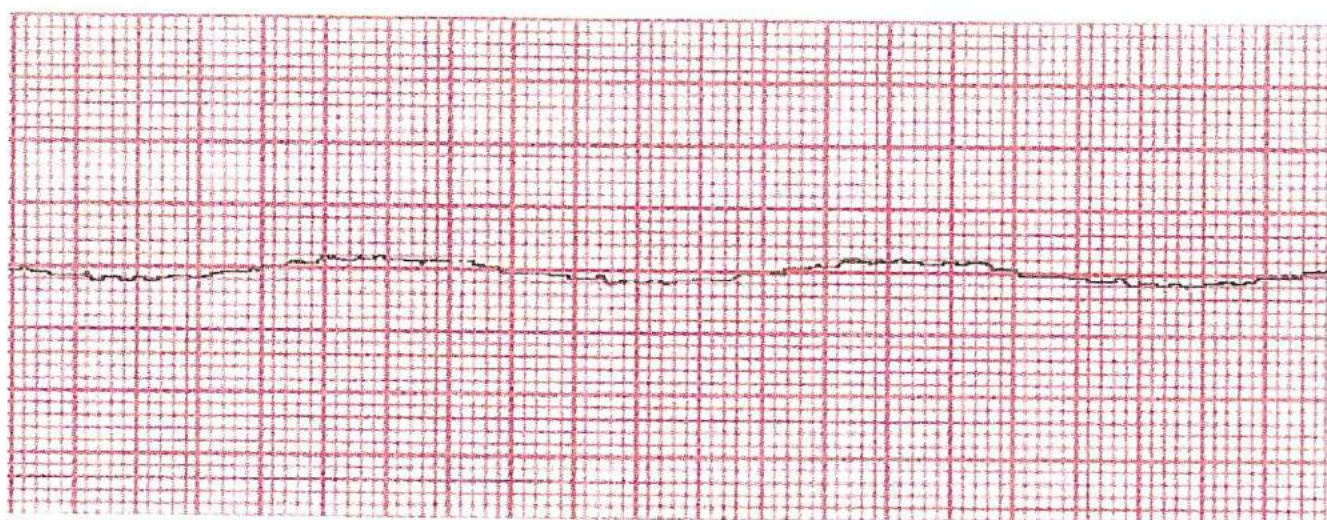
T WAVE: Absent

PACEMAKER SITE: Ventricular

This rhythm is also called “a bag of worms”, it may be seen as coarse or fine VT.

This is to be treated as cardiac arrest.

Asystole (Flat Line)



RHYTHM: Absent

RATE: Absent

P WAVE: Absent

P WAVE same: Absent

P WAVE before QRS: Absent

QRS after P WAVE: Absent

P-R INTERVAL: Absent

QRS COMPLEX: Absent

S-T SEGMENT: Absent

T WAVE: Absent

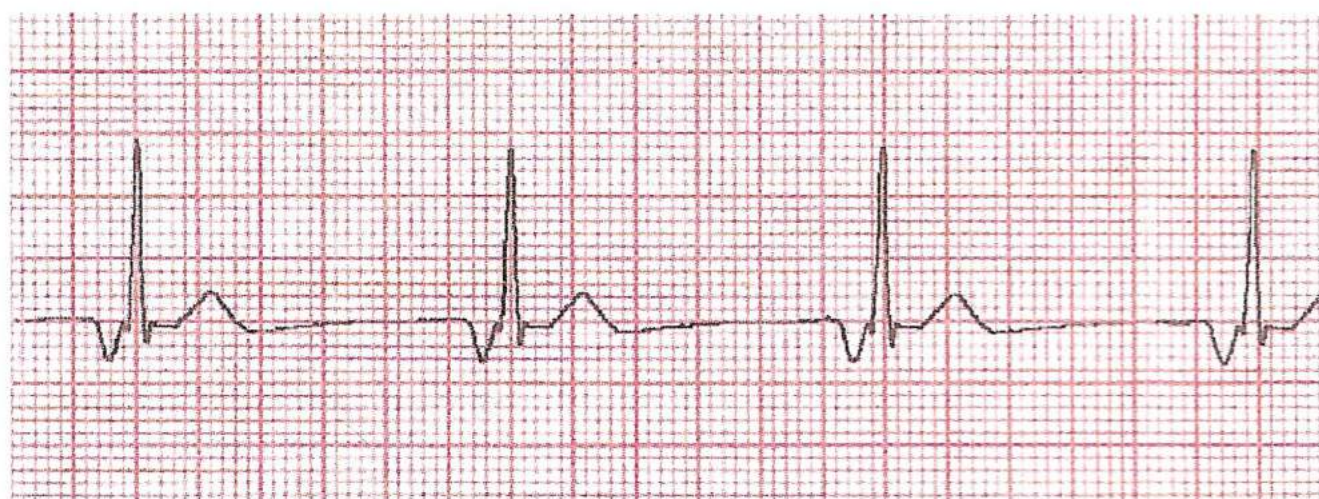
PACEMAKER SITE: None

If after checking that:-

1. The patient is not talking to you.
2. The leads are still attached.
3. Nobody has cut the leads.
4. Pulse is absent.
5. Turn up gain on machine.

Then treat as cardiac arrest.

Junctional or Nodal Rhythms



RHYTHM: Regular

RATE: Normally below 60 beats per minute

P WAVE: Inverted (see below)

P WAVE same: Yes

P WAVE before QRS: Yes

QRS after P WAVE: Yes

P-R INTERVAL: Normally 3 - 5 small squares

QRS COMPLEX: Normal

S-T SEGMENT: Isoelectric

T WAVE: Normal

PACEMAKER SITE: Atrio ventricular node (AV node)

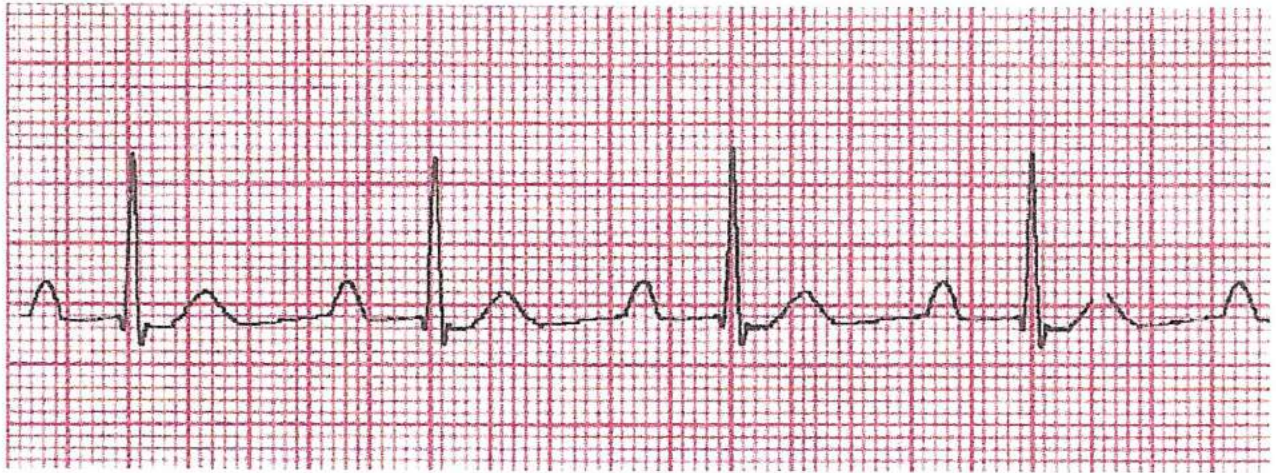
The rhythm can be high nodal, mid nodal or low nodal.

High has an inverted P Wave before the QRS complex.

Mid has a notch in a normal duration QRS.

Low has an inverted P Wave after the QRS complex but before the T Wave.

1° Heart Block



RHYTHM: Regular

RATE: Normally normal

P WAVE: Present, normal

P WAVE same: Yes

P WAVE before QRS: Yes

QRS after P WAVE: Yes

P-R INTERVAL: Greater than 5 small squares

QRS COMPLEX: Normal

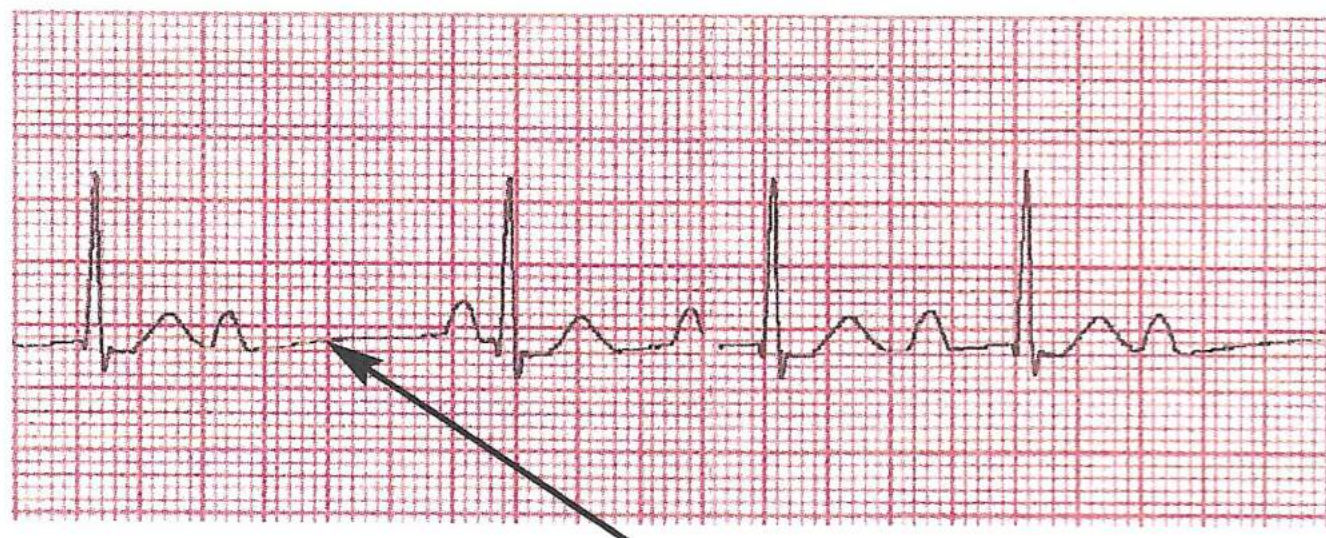
S-T SEGMENT: Isoelectric

T WAVE: Present, normal

PACEMAKER SITE: Sino atrial node (SA node)

With this rhythm the AV node is slow in passing on the impulse to the ventricles which act normally.

2° Type 1 Heart Block (Wenkebach)



Missing QRS complex

RHYTHM: Regular

RATE: Normally below 60 beats per minute

P WAVE: Present

P WAVE same: Yes

P WAVE before QRS: Mostly until dropped beat

QRS after P WAVE: Not when dropped

P-R INTERVAL: Lengthening until dropped beat

QRS COMPLEX: Normal duration when present

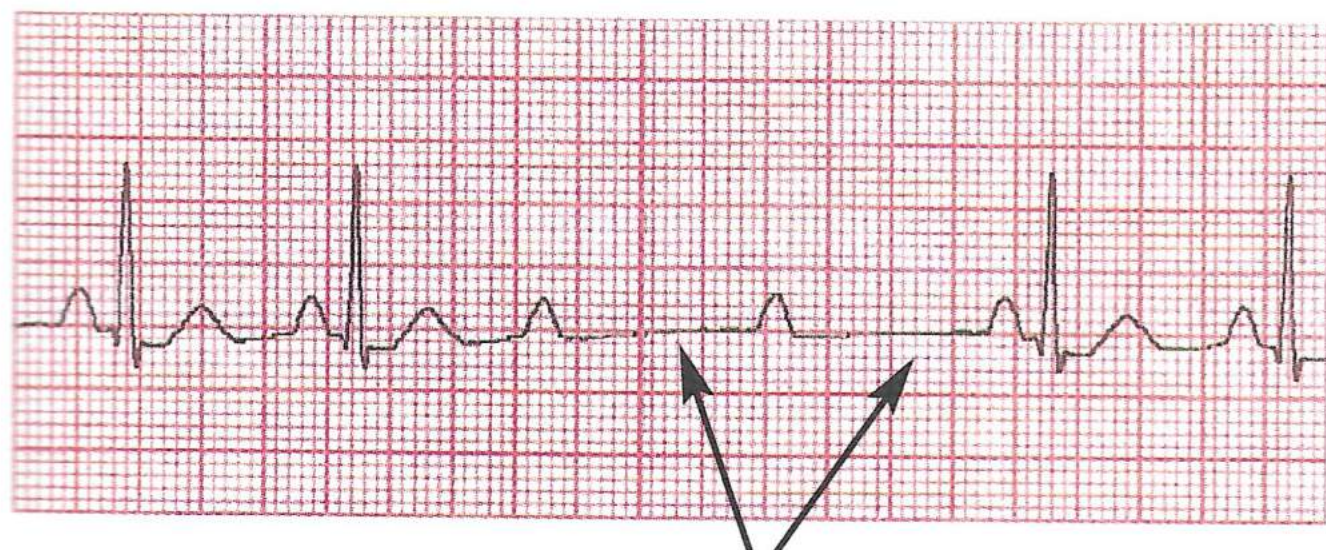
S-T SEGMENT: Isoelectric

T WAVE: Present except at dropped beat

PACEMAKER SITE: Sino atrial node (SA node)

This rhythm has a lengthening P-R interval until no impulse is passed through the AV node. This causes a dropped beat, that is, the ventricles do not contract.

2° Type 2 Heart Block (Mobitz)



Missing QRS complexes

RHYTHM: Irregular but can be regular

RATE: Normally normal

P WAVE: Present

P WAVE same: Yes

P WAVE before QRS: Yes except at dropped beat

QRS after P WAVE: Yes except at dropped beat

P-R INTERVAL: Normal except at dropped beat

QRS COMPLEX: Normal when present

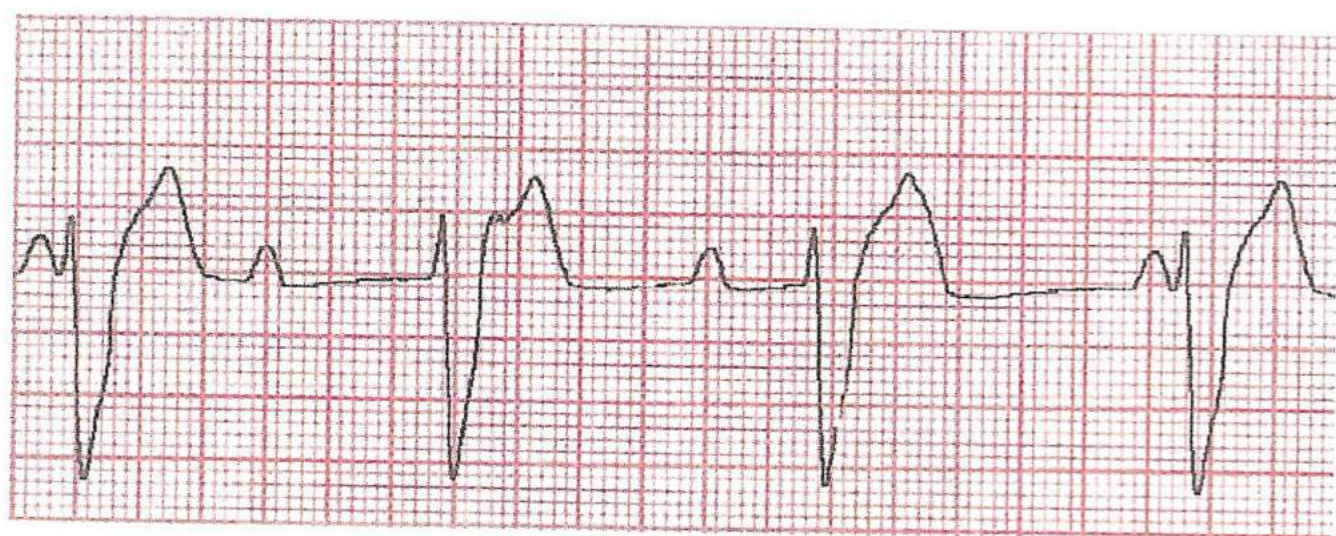
S-T SEGMENT: Isoelectric

T WAVE: Normal when present

PACEMAKER SITE: Sino atrial node (SA node)

With this rhythm the P-R interval is the same for each beat except when the AV node blocks an impulse. This can be on a regular rate, i.e., 2:1, 3:1, 4:1 – in other words, 2 P Waves to each QRS, 3 P Waves to each QRS etc.

3° Heart Block (Complete Heart Block)



RHYTHM: Atrials regular, ventricles regular

RATE: P Waves 70 pm. QRS 30 pm. (approx.)

P WAVE: Present

P WAVE same: Yes

P WAVE before QRS: Sometimes

QRS after P WAVE: Sometimes

P-R INTERVAL: Not measurable

QRS COMPLEX: Wide and bizarre

S-T SEGMENT: May be normal

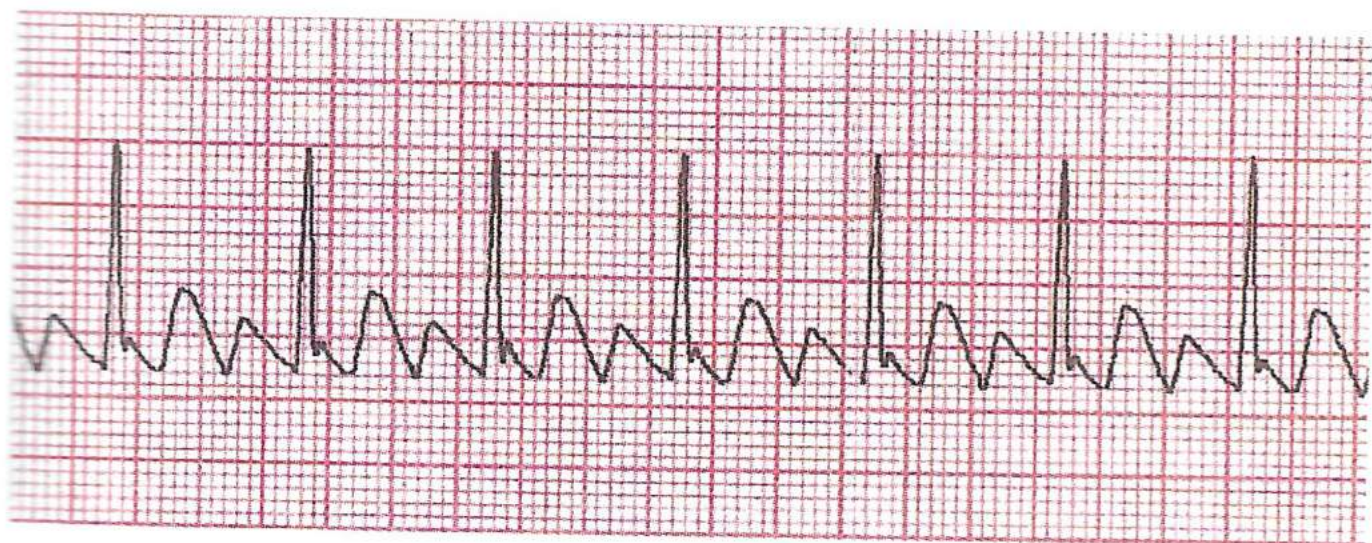
T WAVE: Inverted

PACEMAKER SITE: Sino atrial node and ventricular

With this rhythm the SA node sends impulses to the AV node which completely blocks them so the ventricles fire off at their own intrinsic rate. Occasionally the P Wave and QRS marry up.

If ventricular focus is close to normal pathway then the QRS will appear normal. If ventricular focus is far away from the normal pathway then the QRS will appear to be wide and bizarre.

Atrial Flutter



RHYTHM: Regular

RATE: Normally normal

P WAVE: Large F Waves

P WAVE same: Similar

P WAVE BEFORE QRS: 2, 3, or 4 F Waves before QRS

QRS AFTER P WAVE: After 2, 3 or 4 F Waves

P-R INTERVAL: Not measurable

QRS COMPLEX: Normal

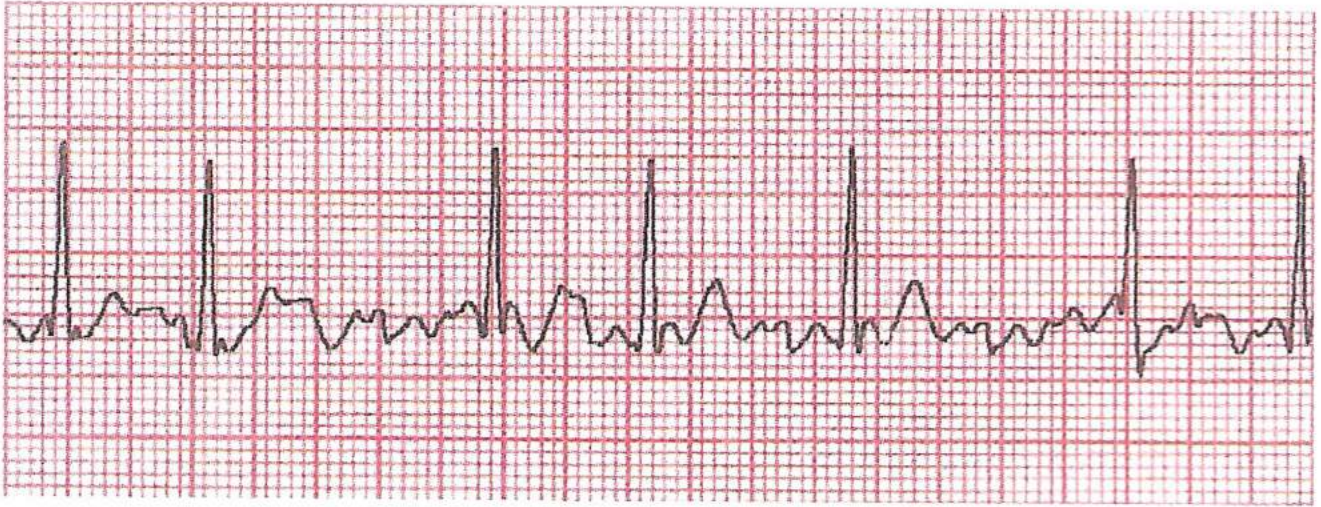
S-T SEGMENT: Isoelectric

T WAVE: Normal

PACEMAKER SITE: Atrial but not necessarily SA node but normally close to

With this rhythm the atria fire off pulses at too fast a rate for the AV node to send on each one but passes on every other or every second or third impulse. QRS is normal.

Atrial Fibrillation



RHYTHM: Irregular

RATE: Can be normal but also fast or slow

P WAVE: No. but small F Waves

P WAVE SAME: No, cannot be seen

P WAVE BEFORE QRS: No, cannot be seen

QRS AFTER P WAVE: No, cannot be seen

P-R INTERVAL: Not measurable

QRS COMPLEX: Normal

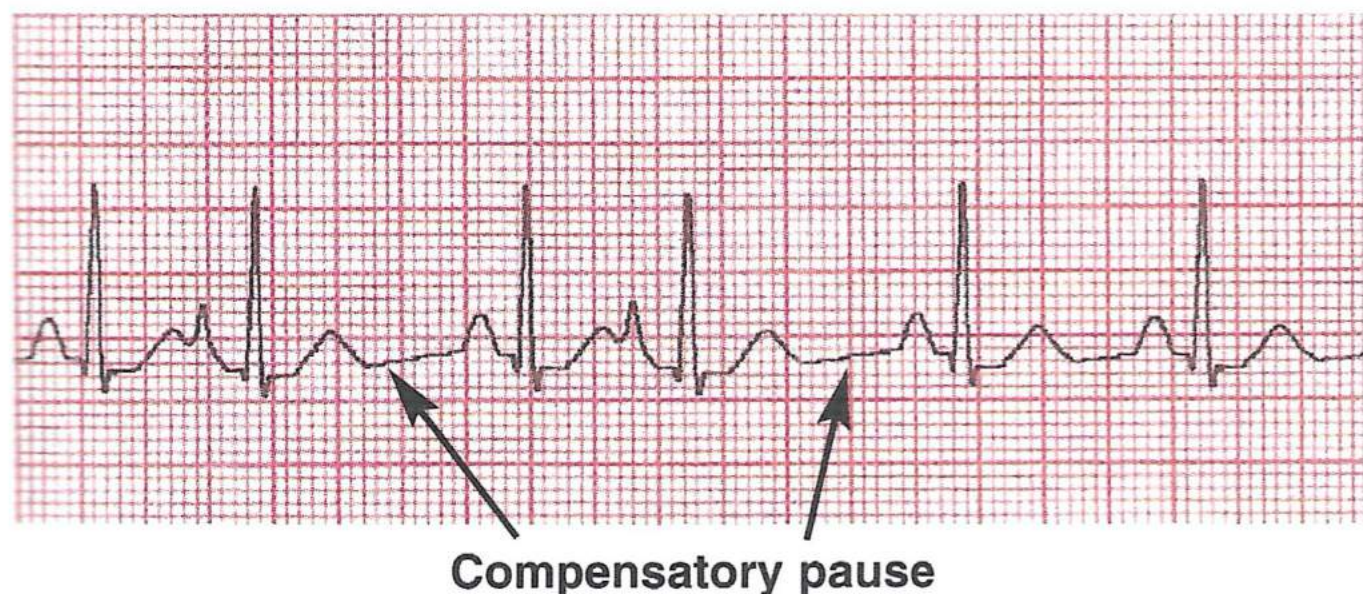
S-T SEGMENT: Isoelectric

T WAVE: Not visible

PACEMAKER SITE: Multi-points in the atria

With this rhythm there are so many impulses firing off in the atria that the AV node cannot cope with the number but lets one through occasionally so the rhythm is irregular but QRS complexes are normal and can be fast, slow or normal.

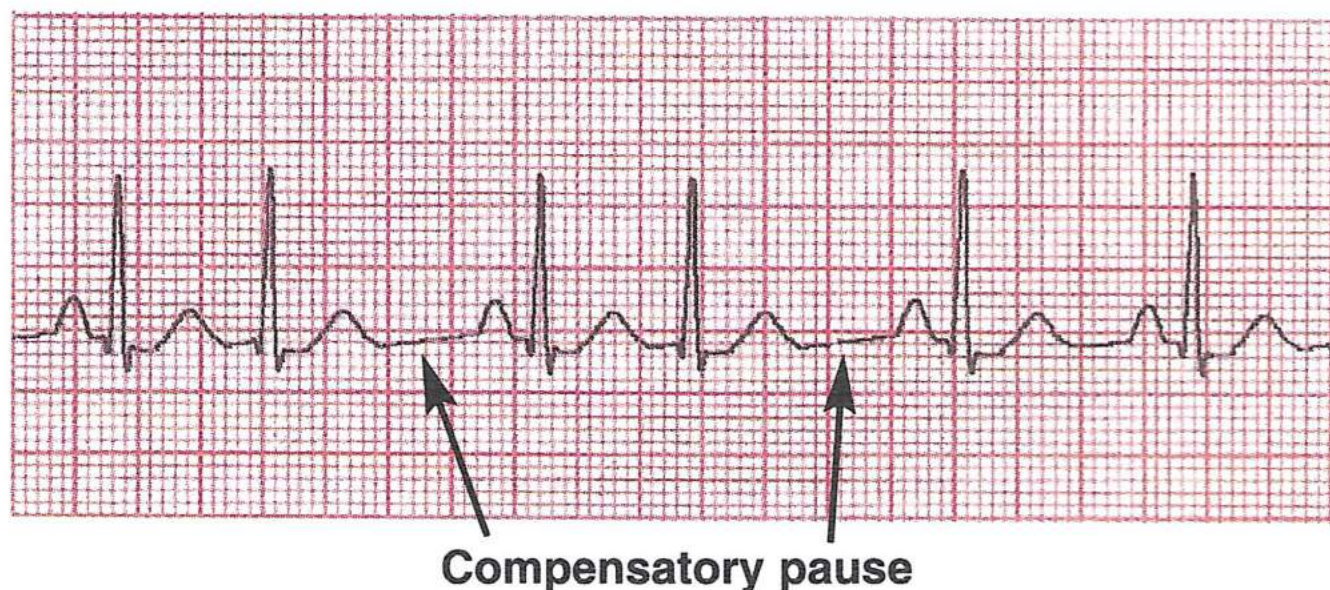
Premature Atrial Contraction (PAC)



Note that:

1. P Wave different from others.
2. The beat has rushed up behind its neighbour.
3. There is a compensatory pause after the premature beat.

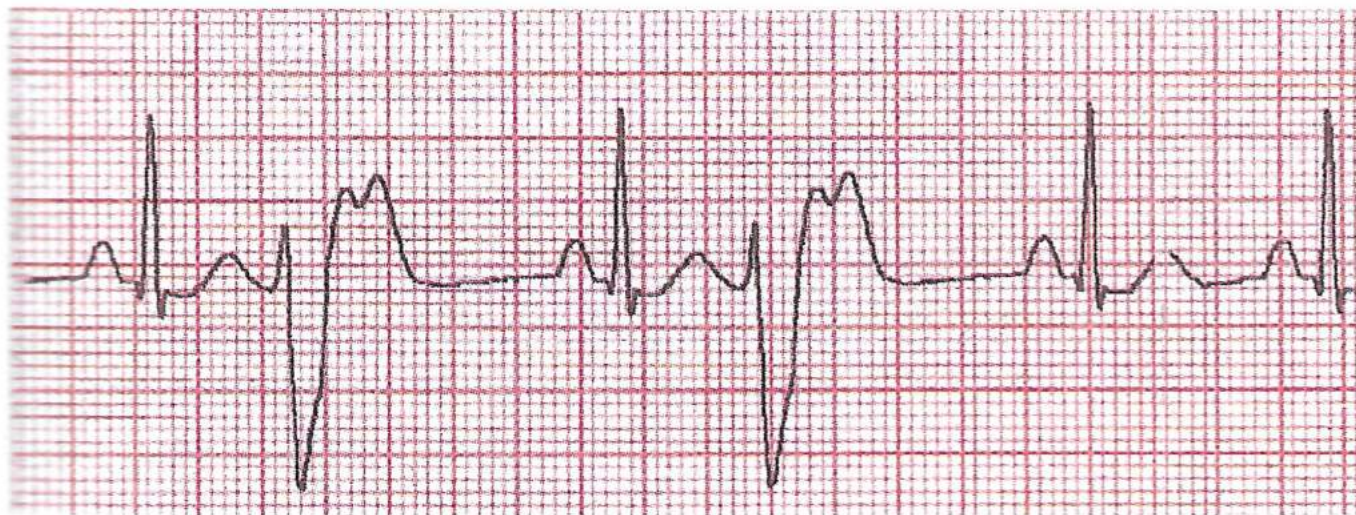
Premature Junctional Contraction (PJC)



Note that:

1. P Wave is inverted
2. The premature beat has rushed up behind its neighbour
3. There is a compensatory pause after the premature beat.

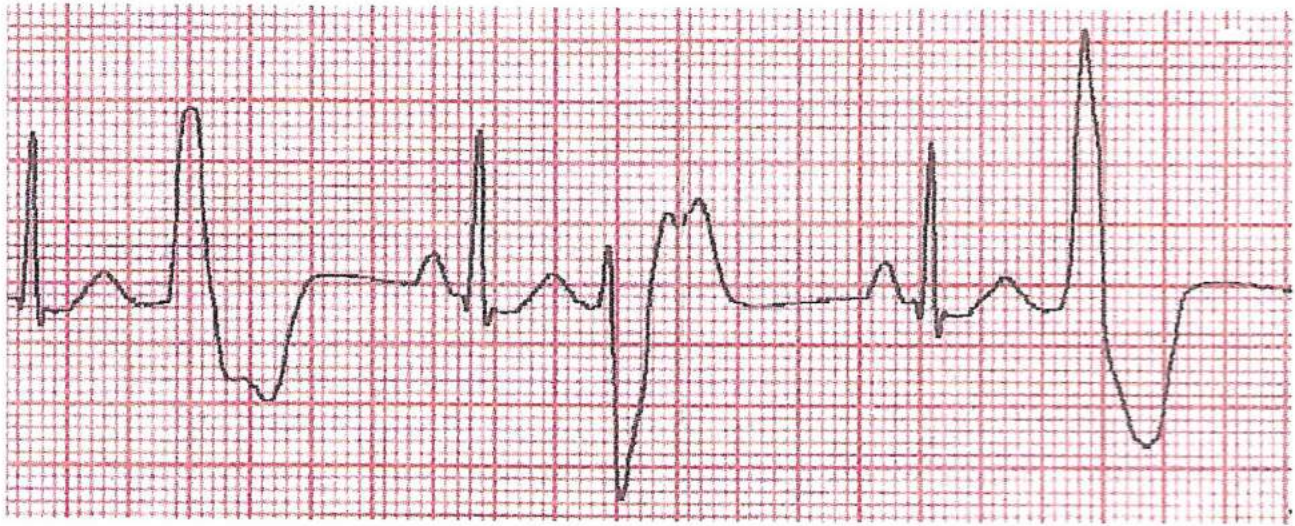
Unifocal Premature Ventricular Contraction (UPVC)



Note that there is:

1. No P Wave and the QRS complex is wide and bizarre.
2. The beat has rushed up behind its neighbour and is the same as the other extra beat.
3. There is often a compensatory pause after it.

Multifocal Premature Ventricular Contraction (MPVC)

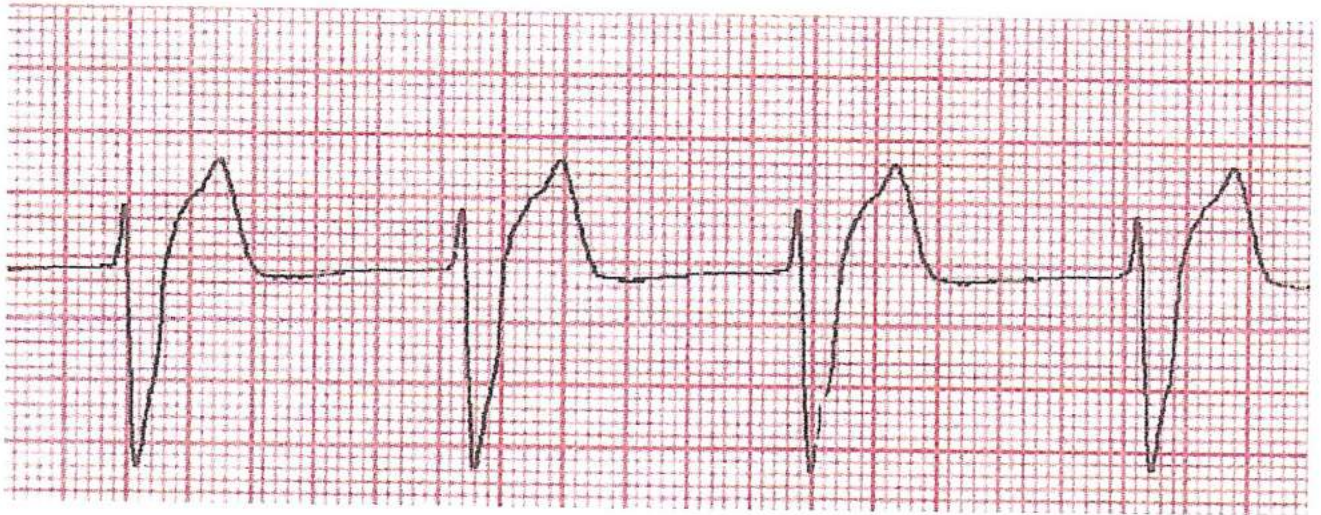


Note that:

1. No P Wave and the QRS is wide and bizarre and that each extra beat is different.
2. It has rushed up behind its neighbour.
3. There is a compensatory pause after it.

A Guide Through the Maze of ECG's

Idioventricular Rhythm (Slow VT)



RHYTHM: Regular

RATE: May be 40 or below

P WAVE: No.

P WAVE SAME: No.

P WAVE BEFORE QRS: No.

QRS AFTER P WAVE: No.

P-R INTERVAL: No.

QRS COMPLEX: Wide and bizarre.

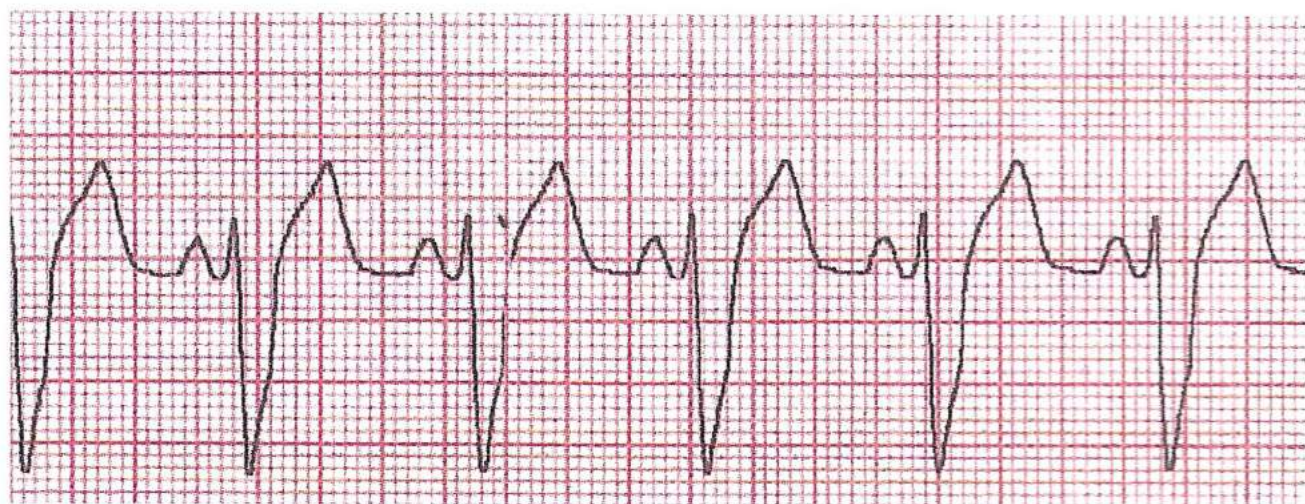
S-T SEGMENT: Depressed.

T WAVE: Inverted.

PACEMAKER SITE: Ventricular.

With this rhythm there is no atrial activity so the ventricles fire off impulses in an escape beat thanks to their intrinsic factor or rate.

Bundle Branch Blocks



RHYTHM: Regular

RATE: Normal

P WAVES: Present

P WAVES SAME: Yes

P WAVES BEFORE QRS: Yes

QRS AFTER P WAVES: Yes

P-R INTERVAL: Normal

QRS COMPLEX: Wider and notched.

S-T SEGMENT: Isoelectric

T WAVE: Normal.

PACEMAKER SITE: Sino atrial node.

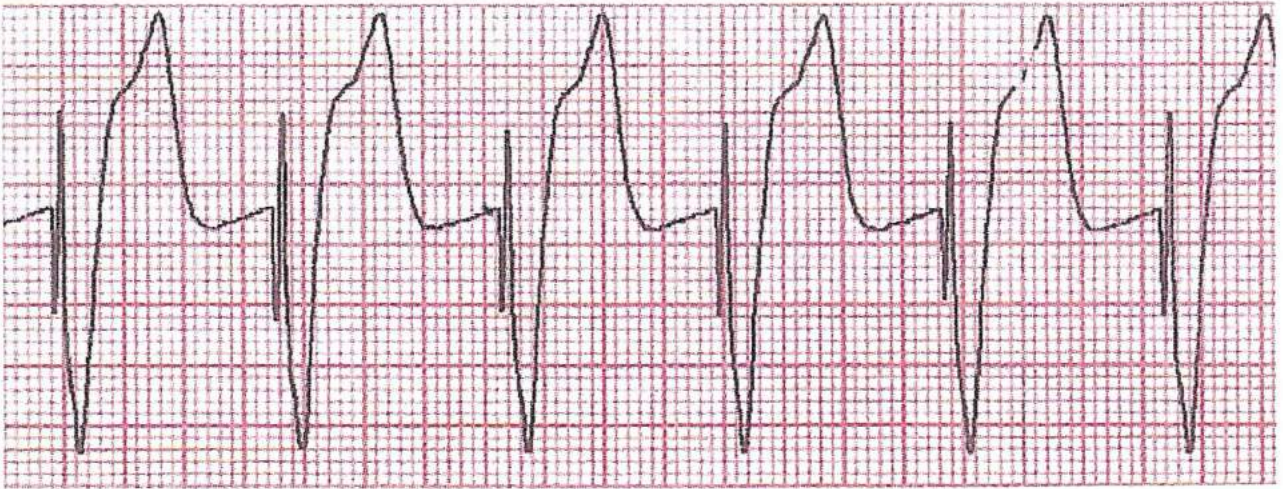This can either be a right bundle branch block or a left bundle branch block and this can only be determined by a 12 lead ECG.

A Guide Through the Maze of ECG's

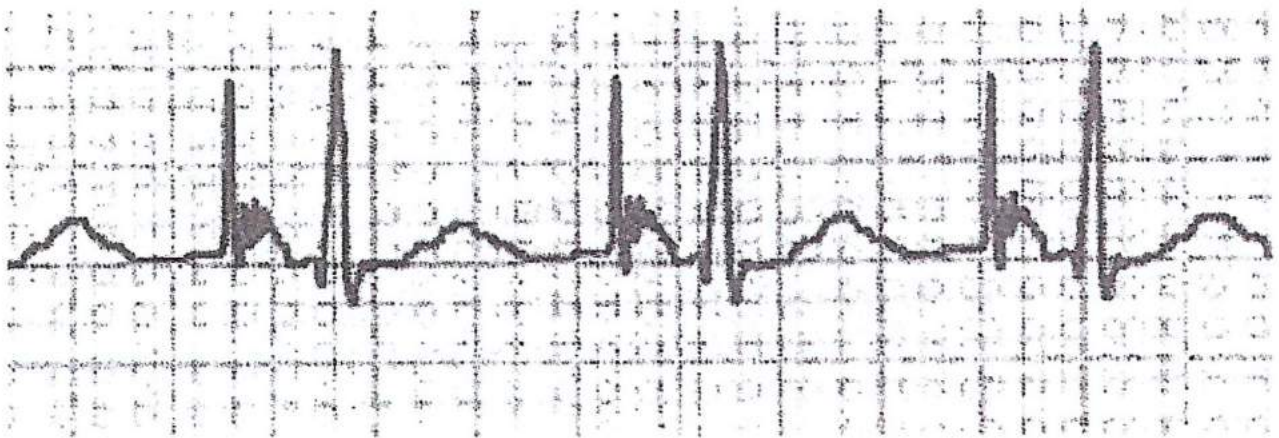
Paced Beats

A short word on pacemakers. There are several types of pacemakers, the most common are:

Ventricular Pacing - i.e. a spike before the QRS complex.

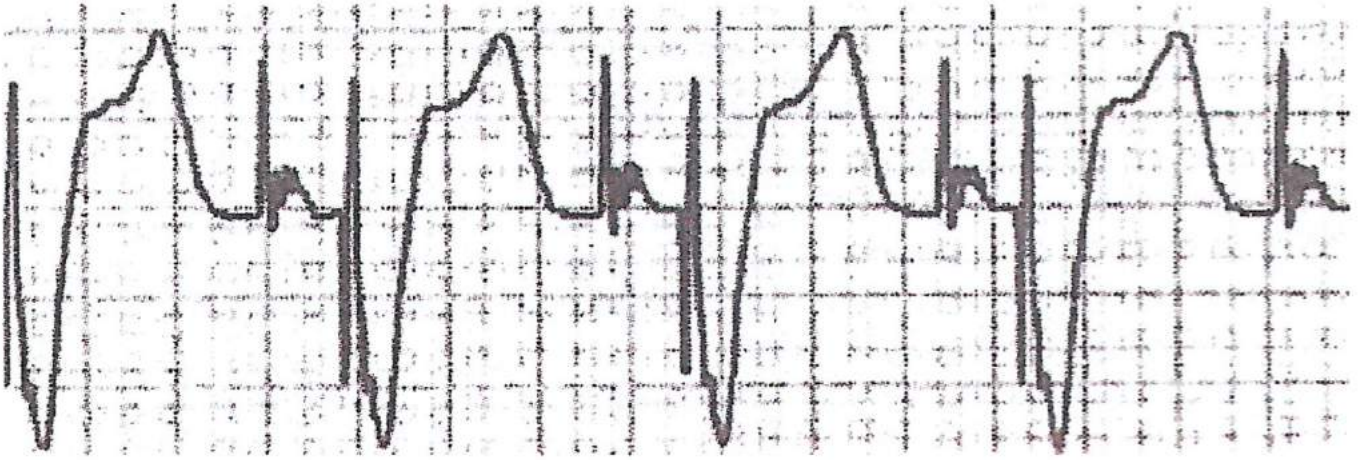


Atrial Pacing - i.e. a spike before the P Wave.



A Guide Through the Maze of ECG's

Dual Chamber Pacing - i.e. a spike before the P Wave then a spike before the QRS complex.

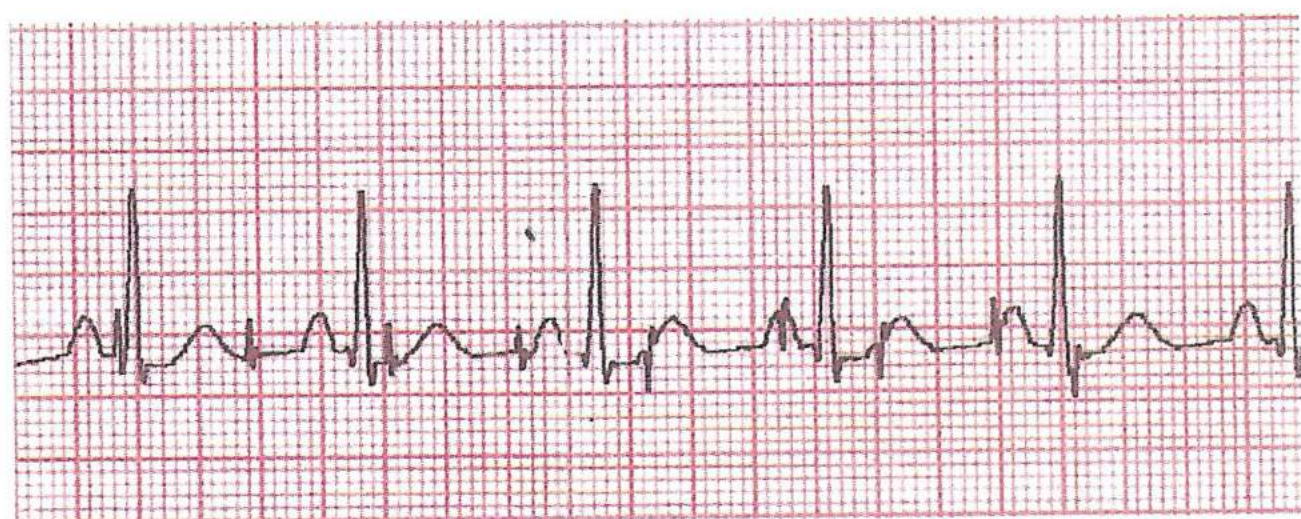


A Guide Through the Maze of ECG's

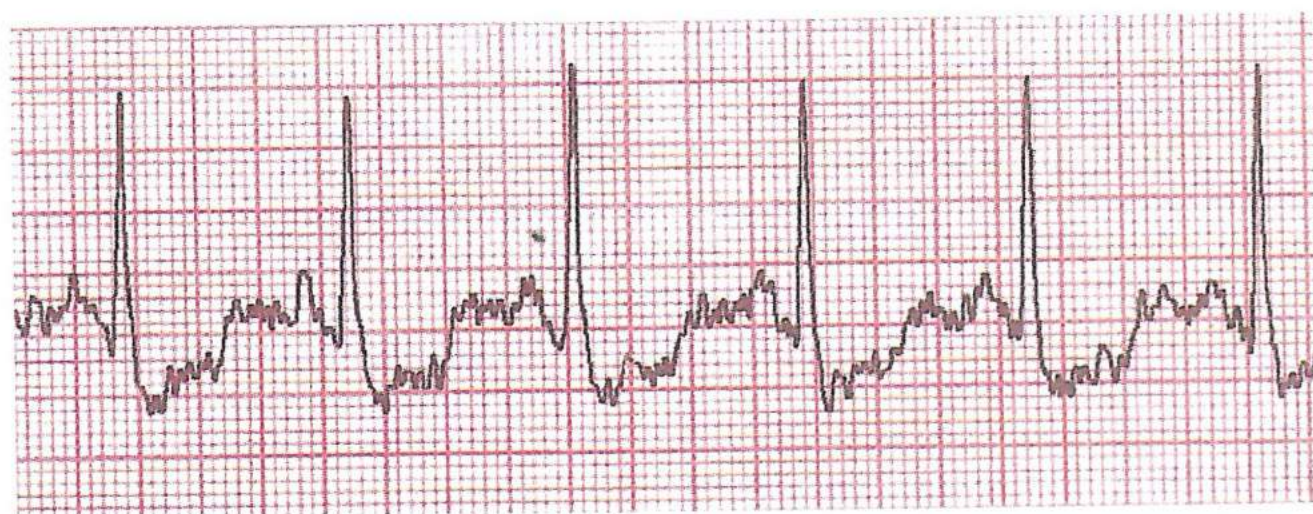
Artefacts

There are basically two types:

60Hzs - electrical activity from the machine.



Muscular tremor - you must have your patient relaxed before running your ECG strip.



A Guide Through the Maze of ECG's

Rhythm Table

	N	A	S	V	V	V	A	J	1°	2°	2°	3°	A	A	A	I	R	R	B
	S	/	V	T	T	F		U	H	H	H	H	F	F	F	I	I	I	I
	R	B	T					N	B	B	B	B	I	I	I	I	I	I	I
Rhythm	R	R	R	I	I	I	O	R	R	I	I	I	R	R	R	R	R	R	R
Rate	70	-60	100+	100+	100+	0	0	60	70	70	70	40	70	70	70	40	40	40	70
P Wave	Y	Y	A	A	A	A	A	IV	Y	Y	Y	Y	A	A	A	A	A	A	Y
P Wave Same	Y	Y	A	A	A	A	A	I	Y	Y	Y	Y	A	A	A	A	A	A	Y
P Wave before QRS	Y	Y	A	A	A	A	A	A	Y	Y	Y	A	A	A	A	A	A	A	Y
QRS after P Wave	Y	Y	A	A	A	A	A	Y	N/A	N/A	N/A	A	A	A	A	A	A	A	Y
P-R Interval	N	N	A	A	A	A	A	O	NL	N/P	N/P	A	A	A	A	A	A	A	Y
QRS Complex	N	N	N	W	W	A	A	N	N	N	N	W	N	N	N	W	W	W	SW
S-T Segment	N	N	N	?	?	A	A	N	N	N	N	?	N	N	N	?	?	?	N
T Wave	Y	Y	Y	IV	IV	A	A	N	N	N	N	IV	N	N	N	IV	IV	IV	N
Pacemaker Size	S.A.	S.A.	Atrial	Ventr	Ventr	Ventr	O	Junc	S.A.	S.A.	S.A.	SAV	Atrial	Atrial	Ventr	Ventr	Ventr	Ventr	S.A.

Y = Yes • A = Absent • N = Normal • R = Regular • I = Irregular • S/W = Slightly Wide • W = Wide • N/P = Normal When Present

N/A = Normally But Sometimes Absent • L = Lengthening • IV = Inverted? • ? = May Or May Not Be Isoelectric

Bibliography

Emergency Care in the Streets

by Nancy L. Caroline, MD

ECG - What Does It Tell?

by J. Gardiner

Extended Training in Ambulance Aid

by NHSTD

Advanced Life Support Manual

by Resuscitation Council

If you can think straight after all the information, I wish to thank you for your indulgence in wading through this book.

I have not covered all the different rhythms and arrhythmias that there are in the world but I hope I have given you a good grounding in ECG recognition. I hope you go on to read other books which cover the subject in more depth than my attempt.

May I wish you a very successful career in whatever field of health care you are in.

STEVE EVANS

State Registered Paramedic

Code:
P/O No:
B/I Date:
BO/606
57969
09/08/16
www.spservices.co.uk



ISBN 0-9534972-5-9



Association of Professional Ambulance Personnel
6 The Old Brewery, The Charlton Estate,
Shepton Mallet, Somerset, BA4 5QE
Tel: 0870 1670999
© 1996 - 2004

3rd Edition - March 2004